

Crohn's Disease with Extraintestinal Manifestations: A Case Report

Yhan Batista, Herry Purbayu***

*Department of Internal Medicine, Faculty of Medicine
Universitas Airlangga/Dr. Soetomo General Hospital, Surabaya

**Division of Gastroenterology and Hepatology, Department of Internal Medicine
Faculty of Medicine, Universitas Airlangga/Dr. Soetomo General Hospital, Surabaya

Corresponding author:

Herry Purbayu. Division of Gastroentero-hepatology, Department of Internal Medicine, Dr Soetomo General Hospital. Jl. Mayjen Prof. Dr. Moestopo No. 6-8 Surabaya Indonesia. Phone: +62-31-550-1177 Facsimile: +62-31-502-3865 Email: herrypsby@gmail.com

ABSTRACT

Crohn's disease (CD) is a chronic debilitating inflammatory disease which mostly affect gastrointestinal tract, but due to its unique features, CD enables to affect extraintestinal organs. Pathophysiology of extraintestinal manifestations is still debatable as many experts propose immune-related hypotheses. It is still unpredictable which manifestation precedes another as studies ongoing. Diagnosing CD is difficult since no gold standards available, therefore clinicians must combine history taking, diagnostic modalities, and a good clinical judgement to diagnose CD. Treatment for CD is not only to treat disease activity, but also to prevent complications to preserve patients' quality of life.

Keywords: *Crohn's Disease, extraintestinal manifestation, chronic diarrhea*

ABSTRAK

Penyakit Crohn merupakan suatu penyakit inflamatorik kronis yang utamanya menyerang saluran pencernaan, namun karena karakteristiknya yang unik, penyakit Crohn dapat menyebabkan gangguan pada organ ekstraintestinal. Patofisiologi gejala masih menjadi perdebatan antar ahli di mana hipotesis terkait imun diajukan sebagai pencetus gejala ekstraintestinal. Awitan gejala ekstraintestinal mendahului gejala penyakit Crohn atau sebaliknya masih belum diketahui secara pasti. Diagnosis penyakit Crohn cukup sulit karena tidak adanya baku emas sehingga para klinisi harus mengkombinasikan anamnesis, modalitas diagnostik dan pertimbangan klinis yang baik untuk menegakkan diagnosis penyakit Crohn. Pengobatan penyakit Crohn ditujukan tidak hanya untuk menekan aktivitas penyakit, namun juga ditujukan untuk mencegah komplikasi untuk mempertahankan kualitas hidup penderitanya.

Kata kunci: *penyakit Crohn, gejala ekstraintestinal, diare kronis*

INTRODUCTION

Crohn's disease (CD) is a chronic inflammatory bowel disease that affects gastrointestinal tract from the mouth to the anus. Crohn's disease often occurs in the second to fourth decades and with typical symptoms of abdominal pain, fever, bloody or non-bloody diarrhea and weight loss.¹ CD incidence rates are reportedly high in Western countries including North America, Europe, the United Kingdom and Scandinavia, while incidence in Eastern Europe is lower and other developing countries are very low although in the last two decades the epidemiology of inflammatory bowel disease has changed. Worldwide CD incidence rates range from 0.1 to 16 per 100,000 individuals. Large-scale research in eight Asian countries showed CD incidence rates between 0.54 and 3.44 per 100,000 individuals.² The prevalence of CD in Indonesia is very low, ranging from 1-10.2% of all patients who underwent colonoscopy with inflammatory symptoms in several hospitals between 2001 and 2007.³

Extraintestinal manifestations occur in about one-third of people with inflammatory bowel disease including PC, with the most common manifestations are peripheral arthritis, aphtous stomatitis, uveitis, erythema nodosum and ankylosing spondylitis while rare manifestations are pyoderma gangrenosum, psoriasis and primary sclerotic cholangitis.⁴ Crohn's disease has the potential to cause disability in his patients. CD patients could face symptoms that are difficult to predict and very disruptive to patients, such as diarrhea, fatigue and urgency, thus requiring long-term care with impacts, the need for medical cares and hospitalizations which decrease patients' quality of life.⁵

This case is reported to apprehend diagnosis of Crohn's disease which, most of times, is tricky due to its various clinical presentations. Diagnostic accuracy may provide early intervention to prevent complications due to disease activities and preserve patients' quality of life.

CASE ILLUSTRATION

A 54-year-old Javanese, male, was referred from a regional hospital with the main complaint of diarrhea since 2 months before admission. The stool is consisted with pulp, mucus and blood. Diarrhea occurred four to six times a day accompanied with frequent abdominal pain mainly on the right side, low-grade fever, decreased appetite and weight loss. Diarrhea is not triggered by certain foods according

to the patient. Urination is considered normal by the patient. The patient had been treated in regional hospital with ciprofloxacin, loperamide and zinc for 2 weeks but felt there was not much development so patient was referred.

The history of diabetes mellitus and hypertension is denied, the patient visited ophthalmology clinic in Dr. Soetomo Hospital because of blurred vision since last 4 months, treated with eye drops but patient did not know the medication and diagnosis. The history of previous bowel surgery is denied. Patients also claim to have joint pain, treated in regional hospitals but not routinely because the patient felt complaints only occurred when he had a heavy workload. The patient is a farmer and heavy smoker, spending 12 – 16 cigarettes per day since youth.

Physical examination showed general appearance is weak, weight 50 kilograms, height 182 cm, body mass index 15.1 kg/m², Glasgow Coma Scale E4V5M6, visual analogue scale 0, blood pressure 0/50 mmHg, pulse 64 x/min, temperature 37,8° celsius, respiratory rate 18 x/min, peripheral oxygen saturation 99% without oxygen supplementation. Neck head examination found anemic conjunctivas. Thoracic examination found no abnormality. Abdominal examination found decreased skin turgor and no pressure tenderness. Extremity examination found no abnormality.

Laboratory examination found leukocytes 7.060/mm³, granulocytes 79.3%, hemoglobin 8.2 g/dL, Hematocyte 29%, MCH 28 pg, MCV 88.3 fl, MCHC 32.3 g/dl, platelets 288,000/mm³, AST 25 U/L, ALT 11 U/L, serum albumin 2.9 mg/dL, bilirubin direk 0.31 mg/dL, bilirubin total 0.62 mg/dL, BUN 29 mg/dL, serum creatinine 0.85 mg/dL, sodium 125 mmol/L, potassium 2.9 mmol/L, chloride 110 mmol/L, random blood sugar 112 mg/dL, LED 46 mm/h. 3-method HIV tests are non-reactive, CEA 7.4 ng/L, CRP 11 mg/dL, Stool examination found leucocytes, erythrocytes, mucus, with no cysts, amoeba, worm eggs, and yeast. Chest X-ray found no abnormality. Plain abdominal X-ray found lumbar spondylosis.

Consultation with ophthalmology concluded acute bilateral conjunctivitis, chronic bilateral uveitis, and bilateral cataracts. The recommendations are to administer levofloxacin eye drop 1 drop every 4 hours in both eyes, atropine eye drop 0.5% 2 drops per eye every 12 hours and steroids according to the therapy department of Internal Medicine.

Patient was diagnosed with chronic diarrhea suspected inflammatory bowel disease with

lumbar spondylosis, acute bilateral conjunctivitis, chronic bilateral uveitis, bilaterla cataracts, anemia, hypokalemia, hypotonic hypovolemic hyponatremia, hypoalbuminemia, hypotensio and moderate dehydration.

Diagnostic plans are colonoscopy and, if needed, esophagogastroduodenoscopy with biopsy. Therapy plans are diet high calories, high protein and low fiber diet, normal saline infusion, intravenous potassium, blood transfusion, and albumin transfusion. Echocardiography found diastolic dysfunction with fraction ejection 75%.

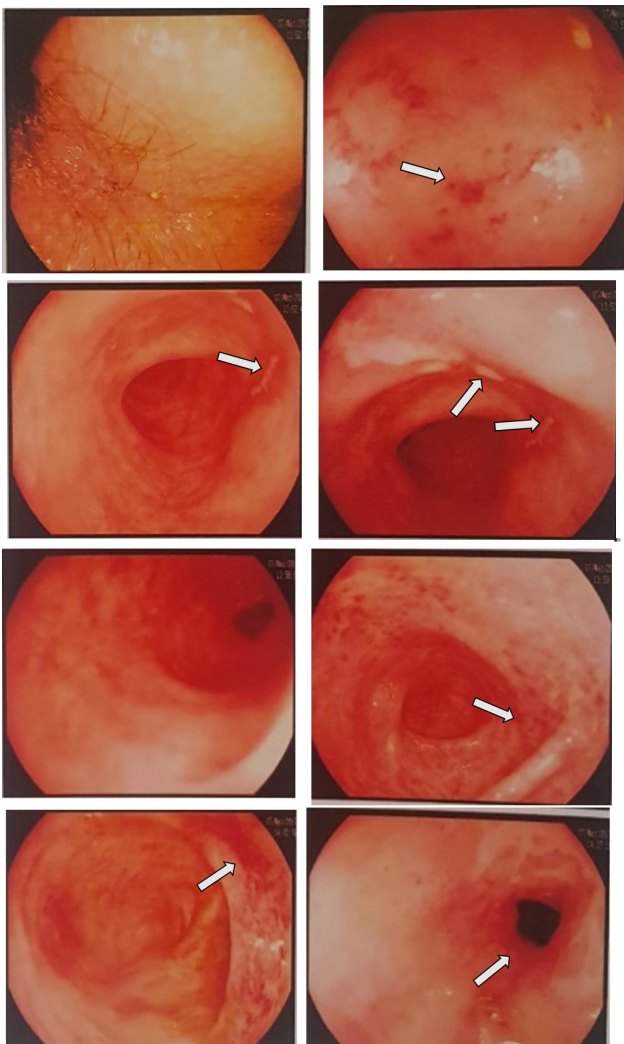


Figure 1. Colonoscopy findings of the patient

Colonoscopy was performed and found visible ulcers from the rectosigmoid to the transverse colon, skip lesions, hyperemia and erosion in the ascending colon, caecum and terminal ileum. The biopsy result is chronic active suppurative colitis.

Esophagogastroduodenoscopy then was performed due to suspicion of CD with the results of edema in gastric mucosal layer, hyperemia and erosion in

fundus, corpus and antrum and duodenum with the conclusion erosive pangastritis and erosive duodenitis. Biopsy results shows active chronic gastritis, chronic duodenitis and negative *H. pylori*.

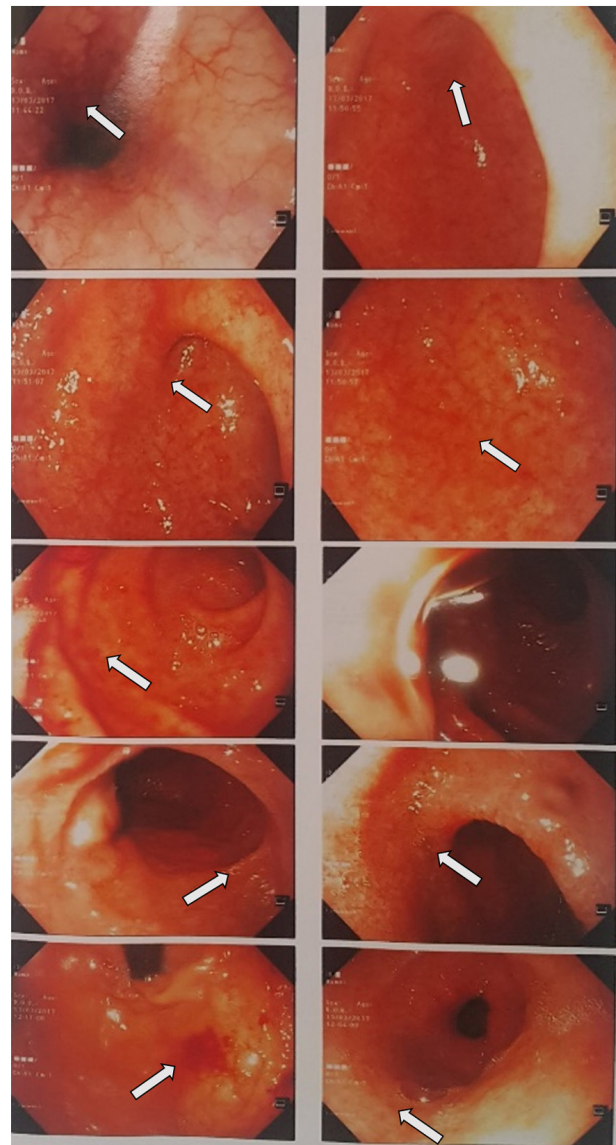


Figure 2. Esophagogastroduodenoscopy findings of the patient

Patient was treated as CD with metronidazole tablets 500 mg every 8 hours peroral, mesalazine tablets 500 mg every 8 hours peroral, methylprednisolone tablets 16 mg peroral every 8 hours, lansoprazole capsules 30 mg every 12 hours peroral and calcium carbonas tablets 500 mg peroral every 8 hours. Complaints about diarrhea and abdominal pain decreased significantly and patient was discharged. Patient is planned to taper off doses of methylprednisolone.

DISCUSSION

Intestinal inflammatory disease is a chronic disease mediated by the immune system in the gastrointestinal

tract with young adult onset characterized by a period of remission and relapse. The main forms of inflammatory bowel disease (IBD) are Crohn's disease and ulcerative colitis (UC).⁶ The etiology of CD is still unclear, but a hypothesis is proposed that etiology is an immune-related condition in genetically vulnerable individuals which disease activity is triggered by environmental factors that weaken mucosal defenses, alter the balance of the intestinal microbiota, and stimulate the intestinal immune response. The three main factors: (1) Genetic; (2) Gut immune response; (3) Microbiota are influenced by environmental exposure or exposome that will trigger CD.⁷

Chronic diarrhea accompanied with or without blood and abdominal pain is the main symptoms of IBD and sometimes accompanied by extraintestinal manifestations as well as systemic symptoms due to pathological conditions such as malnutrition. Crohn's disease has the above characteristics, and the presence of fistulas and abdominal pain is more prominent. The clinical symptoms of IBD is found in Table 1. The clinical symptoms of IBD varies greatly thus good knowledge and clinical judgement are required to distinguish from other diseases whose clinical and pathological features, such as infectious colitis and intestinal tuberculosis.³

A profound history taking including symptoms onset, recent travel history, food intolerance, treatment and appendectomy history as well as risk factors such as smoking, family history of disease and recent gastrointestinal infections should be questioned. Questions regarding extraintestinal manifestations of the mouth, skin, eyes and joints as well as perianal abscesses or anal fissures need to be considered. Physical examination that should be examined include general conditions, pulse, blood pressure, temperature, abdominal pressure tenderness or distension, abdominal mass, oral and perineum examination, rectal examination and body mass index measurement. A single gold standard for establishing CD diagnosis is not yet available. Confirmation of diagnosis through clinical assessment and a combination of endoscopic, histological, radiological and or biochemical examinations. Genetic or serological examinations are still not recommended to diagnose CD routinely.⁸

Endoscopic findings on CD are mainly three types: aphthous ulcers, cobblestone and discontinuous lesions. Aphthous ulcers are characterized by small ulcers that can grow inwards throughout the entire lining of the colon wall while ulcers in the UC are only mucosal

deep. Linear and uneven-edged ulcers can grow several centimeters along the colon's longitudinal axis so that it will form a cobblestone appearance where deep linear ulcers will form a "gap" and inflamed or normal areas will become "stones". CD lesions are discontinuous (skip lesion). Other endoscopic findings but not specific for CDs are normal rectum, the presence of a normal vascularization surround the affected tissue, and terminal ileum involvement.⁹

The key histopathological feature to CD diagnosis is the presence of granulomas, but granulomas can occur in various conditions such as tuberculosis. Granulomas are a collection of monocytes or macrophage cells as well as other inflammatory cells with or without giant cells. Early findings of CD histopathology could be epithelial necrosis, aphthous ulcer or mucosal microulceration. Another image that can be found is the necrosis of the surface of epithelial cells and the crypta of epithelial cells. The degree of similarity of CD histopathological picture with ulcerative colitis is very high but the presence of aphthous ulcers, fissure ulcers, transmural inflammation, fistulas, lymphangiectasia, fibrous structuring and neural changes are suggestive images of CD.¹⁰ In this patient found chronic diarrhea with soft, bloody, and mucous stool for two months accompanied with intermittent abdominal pain with history of heavy smoking. Endoscopic and histopathologic examinations suggest Crohn's disease clinical features, thus patient was diagnosed with Crohn's disease.

The principle of CD therapy is to treat active inflammation until remission occurs, prevent relapse inflammation by maintaining remission for as long as possible as well as treating and preventing complications. CD management consists of general approach, active inflammatory treatment, recurrent inflammatory prevention, complication prevention and surgical procedure.³

General treatment in the form of administration of metronidazole divided doses 1500 - 3000 milligrams per day, intestinal lavage, probiotics and dietary pattern changes by avoiding wheat, cereals, oats and farm products. Active inflammatory treatment aims to induce remission as quickly as possible using corticosteroids and amino salicylic acids. Conventional peroral corticosteroids are highly effective for rapid induction of clinical remission but play no role in maintaining remission. The choice of corticosteroid treatment is budesonide 9 milligrams per day or prednisone 40 – 60 milligrams per day then taper off after remission is achieved within 8 – 12 weeks.

Amino salicylic acid preparation is 5-acetylsalicylic acid (5-ASA) at a dose of 2-4 grams per day until remission occurs and then prescribe an individual maintenance dose. Recurrent inflammatory prevention treatment aims to maintain the remission period for as long as possible using 5-ASA, immunomodulator, anti-tumour necrosis antibody or probiotics. The maintenance dose of 5-ASA is 1,500 – 3,000 milligrams per day. Available immunomodulatory drugs are azathioprine and 6-mercaptopurine (6-MP), cyclosporine, methotrexate as well as other antibiotics that have immunomodulating effects. Azathioprine and 6-MP are used on steroid-dependent or refractory cases at a dose of azathioprine 2.5 milligrams per kgBW or 6-MP 1.5 milligrams per kgBW. Biologic agents such as infliximab are indicated in cases of moderate and severe fistulation. Prevention treatment of recurrent inflammation is good nutrition, dietary changes and psychological support.³ Indications of surgical procedures in CD are complex cases such as fistula, stricture and perianal type CD.¹¹ This patient received low fiber diet, mesalazine, steroid, proton

score is 150 – 220, the activity is moderate when the score is 221 – 450, and the weight when the score is above 450. Crohn's disease is considered responding to therapy if there is a decrease in CDAI score by 70 points.¹² CDAI score of this patient was 221, considered as moderate disease activity.

Inflammatory bowel disease including CD and UC should be considered as a systemic disease, not limited to the gastrointestinal tract because patients will experience extraintestinal symptoms. Extraintestinal symptoms can attack any organ system that will threaten the functional status and quality of life of the patient. Extraintestinal symptoms can be divided into 2 groups, namely extraintestinal manifestations (EIM) and extraintestinal complications. Extraintestinal manifestations can attack joints, skin, hepatobiliary systems, and eyes, as well as the lungs, heart, pancreas, or blood vessels although the frequency is rare. Extraintestinal complications are mainly caused by its disease and conditions such as malabsorption with consequences of micronutrient deficiency, osteoporosis, peripheral neuropathy, kidney stones, gallstones as well as drug-related side effects.¹³

The prevalence of eye disease due to IBD reaches 0.3-13% and 3.5-6.8 % in CD patients. The pathophysiology of ophthalmologic manifestations is still unclear, allegedly due to local activity of antigen-antibody complex against the walls of intestinal blood vessels carried through the bloodstream and autophagy physiological disorders related to macrophages. Uveitis is characterized by dilation of blood vessels causing conjunctival injection, aqueous flares associated with increased vascular permeability and inflammatory cells in the vitreous. Uveitis can be a result of idiopathic, medicinal, or systemic diseases. Treatment of anterior uveitis is a topical steroid to reduce topical inflammation and cycloplegic to prevent ciliary body spasm and pupil spasm related to ocular pain as well as prevent posterior synechia. Chronic uveitis requires immunosuppressant therapy to reduce the duration and side effects of steroid therapy. Cyclosporine, thiopurine, methotrexate, sulfasalazine, and biologic agents of anti-tumor necrosis factor (TNF) are remarkably effective at suppressing IBD activity and IBD-related eye disorders. Anti-metabolite mycophenolate can be used for uveitis therapy but is not indicated in IBD.¹⁴

Cardiovascular manifestations in IBD related to immune-related consequences include pericarditis, myocarditis, thromboembolism, left ventricular disorders, arrhythmias, conduction disorders, infectious

Table 1. Crohn's disease activity index parameter¹²

Variable	Description	Multiplier
Number of liquid stools	Sum of 7 days	x 2
Abdominal pain, graded from 0-3 on severity	Sum of 7 days ratings	x 5
General wellbeing, graded from 0 (well) to 4 (terrible)	Sum of 7 days ratings	x 7
Extraintestinal complications ¹	One point is added for each complication	x 20
Use of antidiarrheal drugs (0= No; 1= Yes)	Use in the previous 7 days	x 30
Abdominal mass (0=none, 2=questionable, 5=definite)		x 10
Hematocrit (Expected-observed Hct)	Observed Hct in males is 47 and for females is 42	x 6
Body weight	[1-(ideal/observed)] x 100	x 1

Arthritis/arthralgia, iritis/uveitis, erythema nodosum, pyoderma gangrenosum, aphthous ulcer, anal fissure/fistule/abscess, fever > 37.8°C
Remission of Crohn's disease is defined as CDAI below 150
Severe disease is defined as value as higher than 450
In Trials, response to medication is often defined as a reduction in the CDAI > 70 points

pump inhibitor and calcium.

A Crohn's disease activity index (CDAI) was developed by Best and colleagues in 1976. Crohn's disease activity index is a criterion used by clinicians to help assess disease activity and therapeutic success. Crohn's disease activity is divided into mild, moderate, and severe based on CDAI score. CD remission is declared when the CDAI score is below 150. Crohn's disease activity is expressed as mild when the CDAI

endocarditis, valvopathy, and Takayasu arteritis. IBD-related chronic inflammatory status affects collagen metabolism which causes stronger collagen deposits in related organs and targets other organs. Incubation of collagen deposits in conjunction with secondary microvascular endothelial dysfunction, changes in mediated vasodilation-nitrite oxide, and deficiency of vitamins as well as essential elements contribute to the occurrence of myocardial fibrosis. Myocardial fibrosis causes left ventricular disorders either diastolic or systolic. Transthoracic echocardiography is a method for the diagnosis of heart failure and evaluation of the systolic and diastolic function of the left ventricle. Systolic dysfunction is characterized by abnormalities of the left ventricular ejection fraction, decreased rates of longitudinal strains of the left ventricle, and kinetic abnormalities of the left ventricular wall. Diastolic dysfunction is characterized by an increase in the ratio of early mitral inflow velocity to early mitral annular diastolic velocity. IBD therapy can have a positive impact on the cardiovascular system as a decrease in inflammatory status will lower cardiovascular risk.¹⁵

Manifestations of arthritis in people with IBD are classified into two categories, peripheral and axial. The pathogenesis of arthritis in IBD is not yet well known, it is suspected that due to the shared epitope between intestinal bacteria and synovia where damage to the intestinal barrier triggers an adaptive immune response so it cannot distinguish between bacterial epitopes and synovia. The incidence of peripheral arthritis in the PC can reach 10-20% and appear as seronegative arthritis. Peripheral arthritis is divided into two types, type I (pauciarticular) and type II (polyarticular). Type I arthritis affects fewer than five joints, such as the ankles, knees, and hips, as acute, asymmetrical, and mobile. Type I arthritis is usually associated with IBD and self-limiting activity within 10 weeks. IBD-related therapy will alleviate complaints of type I arthritis. Type II arthritis is symmetrical and attacks more than 5 joints and is not related to IBD activity, even preceding IBD intestinal complaints. Axial arthritis is less common in IBD patients, only about 3-5%, and unrelated to the intestinal activity of IBD disease. Diagnosis is enforced clinically and radiologically. The peripheral type often does not show a typical picture radiologically while the axial type provides an overview of joint and bone damage, namely in the presence of *squaring* of the vertebral corpus, marginal syndesmophyte, bone proliferation, ankylosis, and sacroiliitis. Treatment of peripheral arthritis of both type I and II is an oral or intraarticular

steroid, immunomodulator, COX-2 inhibitor, and overcoming IBD flares. Therapy for axial arthritis consists of physiotherapy, sulfasalazine, methotrexate, azathioprine and anti-TNF therapy. Anti-TNF such as infliximab and adalimumab provide significant improvements in axial arthritis of IBD patients.¹³ This patient has chronic uveitis, axial arthritis, diastolic dysfunction which correlated with Crohn's disease.

The main cause of anemia in the PC is iron deficiency due to bleeding. Macrocytic anemia can occur due to vitamin B12 deficiency due to diseases of the ileum or resection of ileum, small intestinal bacteria overgrowth (SIBO) or folic acid deficiency which is due to proximal small intestine disease or sulfasalazine therapeutic effect. Excessive production of interferon- γ , *tumor necrosis factor*, or interleukin-1 may inhibit the production of erythropoietin which contributes to causing anemia resistant to iron supplementation.¹⁶

The process of intestinal inflammation decreases the absorption of sodium, chloride, and calcium as well as increases the secretion of potassium. Metabolic alkalosis may occur in PC patients depending on the severity of the disease and the affected part of the gastrointestinal tract.¹⁷ IBD patients experience a relative decrease in body mass and an increase in adipose tissue. This occurs due to poor nutrient intake, increased rate of protein metabolism, and loss of nutrients from the gastrointestinal tract during the active phase of disease or therapeutic effects.¹⁸

The course of PC disease will be an exacerbation of intermittent symptoms with a period of remission. The predictor factors of worsening the course of the disease are the age of fewer than 40 years, the presence of manifestations in the perianal or rectal, smoking, the level of education, and the need for glucocorticoids. The mortality of PC patients is based on population-based studies with a range of no risk until the risk of death increases five times. This wide range is due to variations in the severity spectrum of the disease.⁶

REFERENCES

1. Laass MW, Roggenbuck D, Conrad K. Diagnosis and classification of Crohn's disease. *Autoimmun Rev* 2014;13:467-71.
2. Ng Siew. Epidemiology of inflammatory bowel disease: focus on Asia, best practice and research: clinical gastroenterology. *Best Pract Res Clin Gastroenterol* 2014;28:363-72.
3. Djojoningrat D, Simadibrata M, Abdullah M, Syam AF, Lelosutan SA, Fauzi A. *Konsensus Nasional Penatalaksanaan Inflammatory Bowel Disease (IBD) di Indonesia 2011*. 1st ed. Jakarta: Interna Publishing 2012.p.1-30.

4. Ha F, Khalil H. Crohn's disease: a clinical update. *Therap Adv Gastroenterol* 2015;8:352–9.
5. Van der Have M, van der Aalst KS, Kaptein AA, Leenders M, Siersema PD, Oldenburg B, et al. Determinants of health-related quality of life in Crohn's disease: a systematic review and meta-analysis. *J Crohns Colitis* 2014;8:93–106.
6. Ananthakrishnan NA, Xavier RJ. Inflammatory Bowel Diseases: Pathogenesis. In: Daniel K. Podolsky, Michael Camilleri, J. Gregory Fitz, Anthony N. Kalloo, Fergus Shanahan and TCW, editor. *Yamada's Textbook of Gastroenterology*. 6th ed. Blackwell Publishing; 2016.p.1364-5.
7. Boyapati R, Satsangi J, Ho GT. Pathogenesis of crohn's disease. *F1000Prime Reports* 2015;7:44.
8. Gomollón F, Dignass A, Annese V, Tilg H, Van Assche G, Lindsay JO, et al. 3rd European evidence-based consensus on the diagnosis and management of Crohn's Disease 2016: part 1: diagnosis and medical management. *J Crohn's Colitis* 2017;11:3–25.
9. Roy MA. Endoscopic Diagnosis of Inflammatory Bowel Disease 2016 [serial online] [cited 2018 May 28]. Available from: <https://www.uptodate.com/contents/endoscopic-diagnosis-of-inflammatory-bowel-disease>.
10. Geboes K, De Hertogh G. Indeterminate colitis. *Inflamm Bowel Dis* 2003;9:324–31.
11. Feuerstein JD, Cheifetz AS. Crohn disease: epidemiology, diagnosis, and management. *Mayo Clin Proc* 2017;92:1088-103.
12. Gajendran M, Loganathan P, Catinella AP, Hashash JG. A comprehensive review and update on Crohn's disease. *Dis Mon* 2018;64:20-57.
13. Vavricka SR, Schoepfer A, Scharl M, Lakatos PL, Navarini A, Rogler G. Extraintestinal manifestations of inflammatory bowel disease. *Inflamm Bowel Dis* 2015;21:1982-92.
14. Troncoso LL, Biancardi AL, De Moraes HV, Zaltman C. Ophthalmic manifestations in patients with inflammatory bowel disease: a review. *World J Gastroenterol* 2017;23:5836-48.
15. Bunu DM, Timofte CE, Ciocoiu M, Floria M, Tarniceriu CC, Barboi OB, et al. Cardiovascular manifestations of inflammatory bowel disease: pathogenesis, diagnosis, and preventive strategies *Gastroenterol Res Pract* 2019;2019:3012509.
16. Sands, B.E. and Siegel C. *Sleisenger and Fordtran's Gastrointestinal and Liver Disease: Pathophysiology, Diagnosis and Management* 10th Ed. In: Feldman, M., Friedman, LE., and Brandt LJ, eds. 10th ed. Philadelphia: Elsevier; 2016.p.1990–2022.
17. Barkas F, Liberopoulos E, Kei A, Elisaf M. Electrolyte and acid-base disorders in inflammatory bowel disease. *Annals of Gastroenterology. The Hellenic Society of Gastroenterology* 2013;26:23–8.
18. Forbes A, Escher J, Hébuterne X, Kłęk S, Krznaric Z, Schneider S, et al. ESPEN guideline: Clinical nutrition in inflammatory bowel disease. *Clin Nutr* 2017;36:321–47.