

Diagnosis of Autoimmune Hepatitis using International Autoimmune Hepatitis Group Scoring

Sigit Triyus Priyantoro*, Harijono Achmad**

* Department of Internal Medicine, Faculty of Medicine
University of Brawijaya/Saiful Anwar Hospital, Malang

** Division of Gastroentero-hepatology, Department of Internal Medicine
Faculty of Medicine, University of Brawijaya/Dr. Saiful Anwar Hospital, Malang

ABSTRACT

Autoimmune hepatitis (AIH) is described as T lymphocyte suppressor disturbance, thus there is formation of autoantibody which attacks surface antigen of liver cells or hepatocytes. Diagnosis of AIH is done after other liver abnormalities have been ruled out. The diagnosis of AIH needs to be done with thorough and careful examination as there is no pathognomonic clinical appearance.

A 22-year-old male patient was referred to Saiful Anwar Hospital because of liver dysfunction with increased serum levels of aspartate transaminase (AST) 757 U/L and alanine transaminase (ALT) 345 U/L. Histological findings after liver biopsy were compatible to AIH. He was formerly admitted to a nearby hospital two months ago and diagnosed with acute viral hepatitis, but his transaminase serum level remains elevated. He had negative hepatitis viral marker, hypergammaglobulinemia, and liver biopsy compatible to AIH. Calculation using International Autoimmune Hepatitis Group (IAIHG) scoring from the American Association for the Study of Liver Disease (AASLD) 2010 showed result of probable diagnosed autoimmune hepatitis. Treatment with methylprednisolone 16 mg once daily and hepatoprotector resulted in decreased transaminase serum level and clinical improvement.

Keywords: autoimmune hepatitis, asymptomatic, increased transaminase

ABSTRAK

Hepatitis autoimun digambarkan sebagai gangguan supresor limfosit T sehingga terbentuk autoantibodi yang menyerang antigen pada permukaan sel hepar atau hepatosit. Diagnosis hepatitis autoimun merupakan diagnosis setelah penyebab kelainan hati lain disingkirkan. Penegakan diagnosis hepatitis autoimun memerlukan pemeriksaan yang cermat dan seksama karena gambaran klinis yang tidak patognomonis.

Seorang pasien laki-laki usia 22 tahun dirujuk ke Rumah Sakit Saiful Anwar karena disfungsi hati dengan peningkatan kadar serum transaminase, AST 757 IU/L dan ALT 345 IU/L. Hasil temuan histologis setelah biopsi hati menunjukkan kesesuaian dengan hepatitis autoimun. Pasien sebelumnya dirawat di rumah sakit dua bulan yang lalu dan didiagnosis hepatitis akut, akan tetapi kadar serum transaminase terus meningkat. Hasil pemeriksaan seromarker hepatitis negatif, dengan hipergammaglobulinemia dan biopsi hati yang sesuai dengan hepatitis autoimun. Penegakan diagnosis dengan sistem skoring International Autoimmune Hepatitis Group dari the American Association for the Study of Liver Disease (AASLD) 2010 juga menunjukkan kemungkinan diagnosis autoimun hepatitis. Pengobatan dengan metilprednisolon oral 16 mg perhari dan hepatoprotektor menghasilkan penurunan kadar serum transaminase dan perbaikan gejala klinis.

Kata kunci: hepatitis autoimun, asimtomatis, peningkatan serum transaminase menetap

INTRODUCTION

Autoimmune hepatitis (AIH), is an inflammation of the liver with unknown etiology.¹ Autoimmune hepatitis is described as T lymphocyte suppressor disturbance, thus there is formation of autoantibody which attacks surface antigen of liver cells or hepatocytes, causing progressive necroinflammation or if continues may develop into fibrosis process in liver cells.²

Autoimmune hepatitis is more dominant in young age with the comparison of female to male 3.6 : 1, and may happen in all ethnic. Epidemiology data in Norway and Sweden revealed that the average incidence of autoimmune hepatitis is 1-2 cases per 100,000 population per year, with prevalence of 11-17 incidence per 100,000 population per year.^{3,4} As much as 25% incidence of autoimmune hepatitis manifest as acute hepatitis and signs of other autoimmune diseases, including fever, malaise, urticaria rash, poliartthritis, or glomerulonephritis, most others are asymptomatic and known during the appearance of chronic liver disease.^{5,6}

Diagnosis of autoimmune hepatitis is a diagnosis after other liver abnormalities have been ruled out, because no pathognomonic appearance or specific laboratory test is found. In the American Association for the Study of Liver Disease (AASLD) practice guideline 2010, diagnosis of autoimmune hepatitis is based on abnormal liver histology, clinical characteristics, abnormal globulin serum level, and presence of one or more autoantibody.⁸⁻¹² The background of this case report is problem in establishing the diagnosis of autoimmune hepatitis due to not pathognomonic clinical appearance, thus thorough and careful examination is needed.

CASE ILLUSTRATION

A 22 year old male visited Division of Gastroentero-hepatology, Department of Internal Medicine, Saiful Anwar Hospital, Malang, with chief complaint of easily fatigue after activity since approximately two months. Two months before, patient complained of fever, nausea and vomiting and body weakness after strenuous activity. Patient has been hospitalized for a week and diagnosed with acute hepatitis in a private hospital in Jakarta. However, after two months patient still complained of body weakness after strenuous activity and continuous increase of aspartate transaminase (AST) and alanine transaminase (ALT). History of treatment in patient include the administration of hepatoprotector tablet once daily for two months, no history of past illness and history of

familial hepatitis; furthermore, patient often had high level of transaminase level since the last 6 months.

Physical examination resulted looked moderately ill, body height 173 cm, body weight 70 kg. Blood pressure 110/70 mmHg, heart rate 67 bpm, respiratory rate 16 bpm, temperature 36.8°C. There was no signs of anemic, icteric, cyanosis or even edema. Liver and spleen examination were normal, normal bowel sound. From laboratory examination, results of complete blood count were hemoglobin 16.9 g/dL, leukocyte 7,500/uL, thrombocyte 333,000/uL. Results of kidney function tests were urea 19.70 mg/dL, creatinine 0.94 mg/dL. Liver function and hemostasis revealed alanin transaminase (ALT) 122 U/L, aspartate transaminase (AST) 256 U/L, partial thromboplastin time (PTT) = 9.7 seconds (control = 11.1-11.6 seconds), activated PTT (APTT) = 31.4 seconds (control = 28.9-30.6 seconds), total bilirubin = 0.94 mg/dL, direct bilirubin = 0.60 mg/dL, indirect bilirubin = 0.34 mg/dL, alkali phosphatase = 122 U/L, gamma globulin = 117 U/L, albumin = 4.91 U/L. For hepatitis marker: HBsAg (negative index S/CO) = 0.329; anti HAV IgM (negative index) = 0.329, anti HCV (negative S/CO) = 0.074. Autoantibody examinations resulted negative antinuclear antibody (ANA) test, protein electrophoresis (γ -Globulin) showed hipergammaglobulinemia (3.16 g/dL). From results of abdominal ultrasound, there was no sign of inflammation or other pathological condition in the abdomen.

AST changes in patient were 245 U/L, 757 U/L, and 246 U/L respectively in three laboratory test a month before admission to Saiful Anwar Hospital. ALT levels were 757 U/L, 394 U/L, and 116 U/L respectively, also gamma GT 69.7 U/L and 111 U/L in two previous examinations. Patient was only given hepatoprotector which was administered once daily. In the second day of hospitalization liver biopsy was performed to the patient with obtained results as shown in Figure 1 and 2.

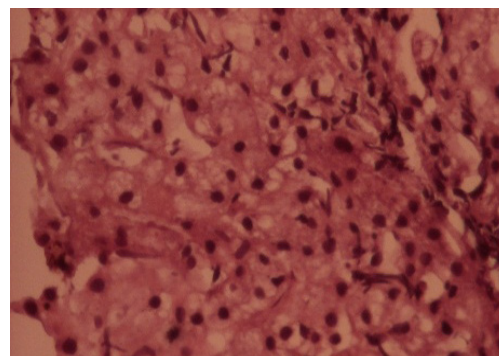


Figure 1. Appearance of hepatocytes showing ballooning changes and Kupffer prominent cell (spindle cell), and rosette at 200x magnification

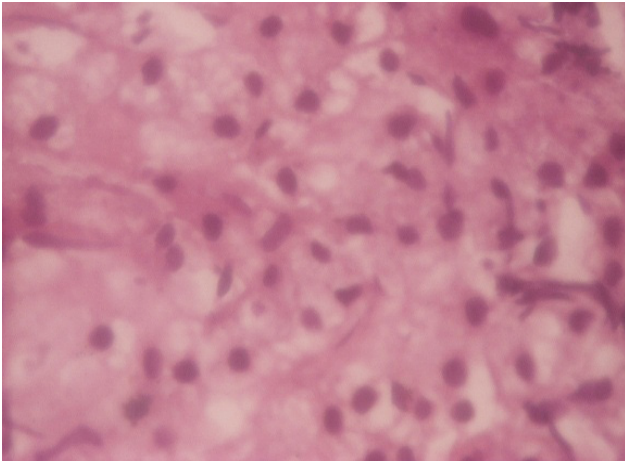


Figure 2. Appearance of inflammatory lymphoplasmatic cell infiltrate in portal track and lymphocyte infiltrate in lobular centro at 400x magnification

Based on clinical evaluation, laboratory, histopathology (rosette appearance and plasma cell infiltration) and negative hepatitis marker, patient was diagnosed with autoimmune hepatitis based on AASLD practice guideline 2010; was given hepatoprotector and corticosteroid which resulted in improvement of transaminase level.

DISCUSSION

In this patient, from anamnesis and physical examination there was no specific appearance, but there was persistent increase in serum transaminase, increase protein electrophoresis results, negative hepatitis A, B, and C result, also liver biopsy result showed plasma cell infiltration and rosettes appearance; this finding could support autoimmune hepatitis description, based on AASLD practice guideline 2010 (class I, level B).⁹

Based on autoimmune hepatitis diagnosis criteria according AASLD practice guideline 2010, in this patient there was negative marker hepatitis, either hepatitis A, B, or C. Daily alcohol consumption was < 25 g/day, laboratory results showed gamma globulin level > 1.5 times from normal cut off. Regarding autoantibody marker, ANA test was performed and showed normal result. Anti liver kidney microsomal (LKM)-1 and α 1-antitrypsin test was not performed because of facility limitation. Appearance in histopathology of liver biopsy in the form of plasma cell infiltration and rosette appearance in liver cells, can support diagnosis of autoimmune hepatitis.

Based on AASLD practice guideline 2010 about autoimmune hepatitis, in 2 recommendations, it is stated that if clinical appearance and laboratory, serology and histopathology are not spesific, establishment of

autoimmune hepatitis diagnosis can use scoring system of IAHG (class IIA, level B).⁹ Patient score 12 was concluded probable diagnosis, so it was still possible that this patient suffered from autoimmune hepatitis, regardless the presence of other autoimmune disease.

Several autoimmune hepatitis case reports including in 2011, in a 58 year old female with Graves disease, initially it was suspected as propyl tiouracil (PTU)-associated hepatitis, but biopsy results showed plasma cell infiltration and rosette appearance in liver tissue and negative hepatitis marker, with scoring the diagnosis of autoimmune hepatitis was established; further, there was improvement with steroid therapy.¹⁷ A case series by Sally et al, showed 3 cases in Caucasian female aged 42, 65, and 74 years old which exhibited spectrum and clinical complaints like patient in this case report, particularly unspecific complaints and normal abdominal USG, but liver biopsy revealed inflammatory cells and plasma cells infiltration.¹⁸

In those three cases, there was report on long-term nitrofurantoin for the prophylaxis of recurrent urinary tract infection, which was suspected to have role in the incidence of autoimmune hepatitis; all three showed clinical improvement after corticosteroid administration, similar to the case we reported.

Based on AASLD scoring, from data of patient's examination, it was obtained ratio of alkali phosphatase and AST < 1.5 U/L (score 2), gamma globulin level 1.5 - 2 times normal level (score 2), negative hepatitis virus marker (A, B, C) (score 3), no history of drugs consumption (score 1), daily alcohol consumption < 25 g/day (score 2), histopathological appearance of liver biopsy showed rosette formation and plasma cell infiltration (score 2).

Patient was given supportive therapy, bedrest and high calorie and protein per oral diet, and corticosteroid therapy (metilprednisolone 16 mg once daily per oral) and hepatoprotector 1 mg daily, with corticosteroid side effect monitoring. Good result was obtained, in the form of clinical symptoms improvement and transaminase level decrease, in day-3, there was decrease of AST 256 U/L, ALT 84 U/L, and evaluation on hospitalization day-7, there was decrease of AST 105 U/L and ALT 60 U/L, with improvement complaints in knowledge representation syntax (KRS) for treatment through outpatient ward.

Data from randomized controled trial (RCT) showed prednisone as single agent or in combination with azathioprine resulted in symptoms improvement, laboratory results improvement, histopathology and survival rate improvement. While, liver transplantation

is definitive therapy in patient who experienced acute liver failure and in patient who already suffer from decompensated liver function. In condition if there is decompensated cirrhosis with model for end-stage liver disease (MELD) score > 15, and hepatocellular carcinoma appearance.¹³⁻¹⁶ Clinicians need to be cautious in the possibility of autoimmune hepatitis in young patients with unspecific symptoms, increase serum transaminase level, and negative hepatitis virus marker examination (A, B, dan C).

REFERENCES

1. Vergani D, Choudhuri K, Bogdanos DP, Mieli-Vergani G. Pathogenesis of autoimmune hepatitis. *Clin Liver Dis* 2002;6:727-37.
2. Czaja AJ. Autoimmune hepatitis. Part A: pathogenesis. *Expert Rev Gastroenterol Hepatol* 2007;1:113-28.
3. Boberg KM, Aadland E, Jahnsen J, Raknerud N, Stiris M, Bell H. Incidence and prevalence of primary biliary cirrhosis, primary sclerosing cholangitis, and autoimmune hepatitis in a Norwegian population. *Scand J Gastroenterol* 1998;33:99-103.
4. Werner M, Prytz H, Ohlsson B, Almer S, Bjornsson E, Bergquist A, et al. Epidemiology and the initial presentation of autoimmune hepatitis in Sweden: a nationwide study. *Scand J Gastroenterol* 2008;43:1232-40.
5. Czaja AJ. Diverse manifestations and evolving treatments of autoimmune hepatitis. *Minerva Gastroenterol Dietol* 2005;51:313-33.
6. Kogan J, Safadi R, Ashur Y, Shouval D, Ilan Y. Prognosis of symptomatic versus asymptomatic autoimmune hepatitis: a study of 68 patients. *J Clin Gastroenterol* 2002;35:75-81.
7. Longmore MB, Wilkinson IB, Davidson EH, Foulkes A, Mafi AR. Autoimmune Hepatitis (AIH). *Oxford Handbook of Clinical Medicine*. 8th ed. New York: Oxford Univ Press 2010.p.268-9.
8. Krawitt EL. Autoimmune hepatitis. *N Engl J Med* 2006;354:54-66.
9. Alvarez F, Berg PA, Bianchi FB, Bianchi L, Burroughs AK, Cancado EL, et al. International autoimmune hepatitis group report: review of criteria for diagnosis of autoimmune hepatitis. *J Hepatol* 1999;31:929-38.
10. Vergani D, Alvarez F, Bianchi FB, Cancado EL, Mackay IR, Manns MP, et al. Liver autoimmune serology: a consensus statement from the committee for autoimmune serology of the International Autoimmune Hepatitis Group. *J Hepatol* 2004;41:677-83.
11. Manns MP, Vogel A. Autoimmune hepatitis, from mechanisms to therapy. *Hepatology* 2006;43:S132-S144.
12. Czaja AJ. Autoimmune hepatitis. Part B: diagnosis. *Expert Rev Gastroenterol Hepatol* 2007;1:129-43.
13. Cook GC, Mulligan R, Sherlock S. Controlled prospective trial of corticosteroid therapy in active chronic hepatitis. *Q J Med* 1971;40:159-85.
14. Soloway RD, Summerskill WH, Baggenstoss AH, Geall MG, Gitnick GL, Elveback IR, et al. Clinical, biochemical, and histological remission of severe chronic active liver disease: a controlled study of treatments and early prognosis. *Gastroenterology* 1972;63:820-33.
15. Murray-Lyon IM, Stern RB, Williams R. Controlled trial of prednisone and azathioprine in active chronic hepatitis. *Lancet* 1973;1:735-7.
16. Seaberg EC, Belle SH, Beringer KC, Schivins JL, Detre KM. Liver transplantation in the United States from 1987-1998: updated results from the Pitt-UNOS liver transplant registry. *Clin Transpl* 1998:17-37.
17. Sato I, Tsunekawa T, Shinohara Y, Nishio Y, Shimizu Y, Suzuki Y, et al. A case of autoimmune hepatitis with grave disease treated by propylthiouracil. *Nagoya J Med Sci* 2011;73:205-9.
18. Sally A, Ruma S, David AG. Autoimmune hepatitis triggered by Nitrofurantoin: a case series. *J Med Case Rep* 2010;4:311.

Correspondence:
Harijono Achmad
Division of Gastroentero-hepatology
Department of Internal Medicine
Dr. Saiful Anwar Hospital
Jl. Jaksa Agung Suprpto No. 2 Malang Indonesia
Phone/Facsimile: +62-341-348265
E-mail: harijono_achmad@yahoo.com
