

# Role of Double Balloon Enteroscopy in the Diagnosis of Obscure Gastrointestinal Bleeding

Segal Abdul Aziz\*, Dadang Makmun\*\*

\* Department of Internal Medicine, Faculty of Medicine, University of Indonesia  
Dr. Cipto Mangunkusumo General National Hospital, Jakarta

\*\* Division of Gastroenterology, Department of Internal Medicine, Faculty of Medicine,  
University of Indonesia/Dr. Cipto Mangunkusumo General National Hospital, Jakarta

## ABSTRACT

*Obscure gastrointestinal bleeding (OGIB) is bleeding in the digestive tract which persist or recur and with unclear aetiology. OGIB is one of the important problems in the gastrointestinal field due to difficulty in diagnosing the aetiology and determining the source of digestive tract bleeding in patients. In diagnosing the cause of OGIB, clinical approach through history taking and physical examination still have important roles. Most of the sources of bleeding in OGIB is from the small intestine, which cannot be reached by esophagogastroduodenoscopy (EGD) or colonoscopy. Therefore, role of diagnostic tool which is able to perform total enteroscopy becomes important in diagnosing the cause of OGIB.*

*Double balloon enteroscopy (DBE) technique is a safe endoscopy procedure which may use oral or even rectal approach. In finding the cause of OGIB, where most of the lesions is found in the proximal region of the small intestine, oral approach is more beneficial. When bleeding is not found after conventional endoscopy is performed, it needs to be suspected that the source might come from the small intestine. Currently, the two main modalities which can be used in the evaluation are video capsule endoscopy (VCE) and DBE. However, based on cost effectiveness DBE without prior VCE has benefit because it can also administer therapy in the abnormalities being found.*

**Keywords:** *obscure gastrointestinal bleeding, endoscopy, diagnosis, double balloon enteroscopy*

## ABSTRAK

*Perdarahan saluran cerna tersembunyi merupakan perdarahan saluran cerna yang persisten atau terjadi berulang kali dan tidak jelas penyebabnya. Perdarahan saluran cerna tersembunyi merupakan salah satu masalah penting dalam bidang gastrointestinal dikarenakan sulitnya mendiagnosis penyebab dan menentukan sumber perdarahan saluran cerna pada pasien. Dalam mendiagnosis penyebab perdarahan saluran cerna tersembunyi, pendekatan klinis melalui anamnesis dan pemeriksaan fisik tetap memegang peranan penting. Sebagian besar sumber perdarahan pada perdarahan saluran cerna tersembunyi berasal dari usus halus yang tidak dapat dicapai oleh esofagogastroduodenoskopi (EGD) atau kolonoskopi. Oleh sebab itu, peranan alat diagnostik yang dapat melakukan total enteroskopi menjadi penting dalam mendiagnosis penyebab perdarahan saluran cerna.*

*Teknik enteroskopi balon ganda merupakan prosedur endoskopi yang aman dan dapat digunakan dalam pendekatan melalui oral maupun rektal. Dalam hal mencari penyebab perdarahan saluran cerna tersembunyi, dimana sebagian besar lesi ditemukan di usus halus bagian proksimal, pendekatan melalui oral lebih menguntungkan. Perdarahan yang tidak ditemukan setelah dilakukan endoskopi konvensional, patut dicurigai sumbernya berasal dari usus halus. Dua modalitas utama saat ini yang dapat digunakan untuk mengevaluasinya adalah video kapsul endoskopi dan enteroskopi balon ganda. Namun, secara efektifitas biaya, enteroskopi balon ganda tanpa didahului oleh video kapsul endoskopi memiliki kelebihan karena dapat sekaligus memberikan terapi pada kelainan yang ditemukan.*

**Kata kunci:** *perdarahan saluran cerna tersembunyi, endoskopi, diagnosis, enteroskopi balon ganda*

## INTRODUCTION

Obscure gastrointestinal bleeding (OGIB), is a problem in gastrointestinal field. This is caused by the difficulty in diagnosing the cause and determine the source of gastrointestinal bleeding in the patient. Patient usually come with complaint of iron deficiency anemia, or may also come with several episodes of melena and red coloured stool. In United States, OGIB contributes 5-10% from all digestive tract bleeding each year. From those cases, 75% of bleeding site is found in the small intestine.<sup>1,2,3</sup>

Small intestinal bleeding, unless it is massive, is usually difficult to detect. This is because basically, small intestine is not the common source of bleeding site, and also the location cannot be reached by using advanced scope. Other supporting examination such as radiology with contrast (barium) also sometimes difficult in evaluating the presence of bleeding because of the length and number of loops in the small intestine. Additionally, small intestinal bleeding is slow and intermittent, thus it is more difficult to detect.<sup>1</sup>

The inventions of video capsule endoscopy (VCE) and double balloon enteroscopy (DBE), open a new paradigm in diagnosing and treating OGIB cases. Lesions and bleeding source in the small intestine can be detected using both of these tools, even DBE may assist in the treatment of small intestinal bleeding without the need of performing intraoperative enteroscopy.<sup>1</sup>

In this literature review, we will discuss the diagnostic approach in OGIB, role of DBE, and a glimpse about position of other modalities in diagnosing the cause of OGIB.

## OBSCURE GASTROINTESTINAL BLEEDING

Obscure gastrointestinal bleeding (OGIB) is a persistent or recurrent gastrointestinal bleeding, without clear cause although initial examinations, including esophagoduodenoscopy (EGD), colonoscopy, or follow-through barium have been performed. OGIB is clearly seen in the form of melena or hematochezia, or may only occult, where only positive occult blood faeces associated with unexplained iron deficiency anemia.<sup>1,2</sup>

Mostly, the source of bleeding in OGIB is from small intestine, but there is also small proportion which originates from upper or lower gastrointestinal tract which is not found in endoscopy examination. How this may happen is explained by several possibilities: 1) Bleeding lesion is unreachable by scope, but is not

recognised as source of bleeding (Cameron lesion, angioectasis, internal haemorrhoid); 2) Bleeding lesion is reached by scope, but is difficult to visualize (covered by blood clot, unrecognised varices in hypovolemic condition, or obscure source of bleeding behind the mucosal fold) or lesion which can appear at any given time (Dieulafoy lesion); 3) Bleeding lesion in the small intestine which is not reached by standard scope.<sup>1,2</sup>

In diagnosing the cause of OGIB, clinical approach through anamnesis and physical examination still hold an important role. From anamnesis, we are able to find out patient's medication history, which may be associated with the cause of bleeding. From family history, we may find out the presence of hereditary vascular abnormality of malignancy in the family.<sup>4</sup>

Lesion in all digestive tract, from esophagus to the colon, may be the cause of OGIB. EGD sometimes may miss in detecting several lesion, such as Cameron erosion in hiatal hernia, fundus varices, angioectasis, Dieulafoy lesion, peptic ulcer, and gastric antral vascular ectasias (GAVE). While lesion which sometimes is not detected through colonoscopy include angioectasis and malignancy.<sup>2,4</sup>

Abnormality in the small intestine which is not detected through EGD or even colonoscopy, usually is influenced by age. In young age below 40 year old, small intestine bleeding is commonly caused by tumor, Meckel diverticulum, or Crohn's disease. While in the age more than 40 year old, bleeding is more likely to be caused by angioectasis or non-steroid anti-inflammatory drugs (NSAIDs).<sup>2,4</sup>

## SMALL INTESTINAL LESION WHICH MAY CAUSE OBSCURE GASTROINTESTINAL BLEEDING

### Angioectasis and Telangiectasia

Angioectasis lesion, or also known as angiodysplasia, is additional blood vessel along the gastrointestinal tract which appear in line with the increase of age. While, telangiectasia is widening of the terminal part of blood vessels. These both lesions may cause obscure bleeding, particularly in those who consume anticoagulant or anti-platelet drugs. Angioectasis and telangiectasia can also be found in patients with systemic diseases, such as kidney failure, cirrhosis, connective tissue disease, or severe cardiovascular diseases. In histopathology appearance, angioectasis has signature characteristic in the form of dilation of submucosal vein.<sup>1,4</sup>

In endoscopy, angioectasis is seen as red lesion with the size of 2-10 mm, with widening blood vessels originating from central blood vessels. Stressing by scope will cause this lesion to look pale. In colonoscopy with anaesthesia, this lesion is even more difficult to identify due to temporary hypotension which cause vasoconstriction response. Angioectasis may appear in the entire gastrointestinal tract with multiple amount in one segment. In a study in United States, angioectasis lesion was found in 1-3% asymptomatic patients who underwent colonoscopy. The most common sites were cecum, sigmoid colon, rectum, and ascending colon. Bleeding in angioectasis lesion is associated with abnormalities in von Willebrand factor.<sup>1,4</sup>

### **Hereditary Haemorrhagic Telangiectasia**

Hereditary haemorrhagic telangiectasia (HHT) known as Osler-Weber-Rendu disease, is a hereditary condition which is autosomal dominant in characteristic, marked by the presence of telangiectasia and diffuse artery venous malformation. Patient usually complained of recurrent bleeding from the nose, gastrointestinal tract, and presence of iron deficiency anemia. Telangiectasia may appear in the entire parts of small intestine. In a case series, where VCE was performed in 32 patients with hereditary haemorrhagic telangiectasia (HHT) and 48 patients without HHT, it was found that 81% telangiectasia in HHT patients compared to 29% in non-HT patients. The source of bleeding usually is in the duodenum and proximal jejunum. The presence of more than 5 lesions of telangiectasia in endoscopy, has sensitivity of 75% and positive predictive value of 86% in diagnosing HHT.<sup>1,4</sup>

### **Blue Rubber Bleb Nevus Syndrome**

Blue rubber bleb nevus syndrome is a syndrome with rarely happen, marked with the presence of arteriovenous malformation on the skin, soft tissue, and gastrointestinal tract. The most common clinical symptoms include haemangioma lesion on the skin or accompanied with iron deficiency anemia. Gastrointestinal bleeding is usually asymptomatic and responded in administration of oral iron preparation. In endoscopy, venous bleb which is prominent and polypoid was found. This lesion can be found particularly in small intestine and colon.<sup>1,4</sup>

### **Meckel Diverticulum**

Meckel Diverticulum is a congenital diverticle due to incomplete obliteration of vitelina duct during

gestation. Other characteristic of this abnormality is known with “rule of twos”, which is happen in 2% population, found in 2 feet distance from ileocecal, 2 inch length, causes complication in 2% cases, may be found in two ectopic tissue in the diverticle (gastric and pancreatic), usually found in the age of 2 year old, and the ratio between male and female 2 : 1. The common complications from this disease is bleeding, obstruction, and diverticulitis and may happen either in children or adult.<sup>1</sup>

Histopathology appearance in this disease is the presence of ectopic gastric mucosa in the diverticle surface which can secrete acid and cause ulcer. The definitive diagnosis of this disease is using technetiumperchnetate which has high affinity to gastric mucosa, known as Meckel’s scan.<sup>1</sup>

### **Non-steroid Anti Inflammatory Drugs**

Erosion or ulceration in small intestine mucosa can be found in 25-55% patients who consume non-selective non-steroid anti-inflammatory drugs (NSAIDs). The incidence decrease in those who consume COX2 inhibitor. The development of NSAIDs in enteric coated or slow release preparation causes the gastrointestinal side effects also deviate to the more distal part (small intestine and colon). NSAIDs is slightly lipophilic thus can directly enter the intracellular of enterocytes cells, increase concentration of intracellular drugs, and disrupt energy metabolism in the mitochondria. The other effect of intracellular NSAIDs are increase of intracellular calcium and free radical production which will disrupt integrity between cells, final results were increase of intestinal permeability and facilitate the occurrence of inflammation.<sup>1,5</sup>

### **Small Intestine Neoplasm**

Incidence of tumour in small intestine is not so frequent, approximately 5-7% of total digestive tract malignancy, but become the most common cause of OGIB in young aged patients. Most common found malignancies are adenoma, adenocarcinoma, carcinoid tumour, stromal tumour, lymphoma, Peutz-Jeghers, syndrome and juvenile polyp.<sup>1</sup>

### **Diverticle**

Small intestine is the common site to form diverticle. As much as 79% cases occur in the duodenum, 18% in jejunum or ileum, and the rest formed in all segments. Small intestinal diverticle lesion rarely causes bleeding, however this may happen in 1-2% cases.<sup>1</sup>

### Small Intestine Dieulafoy Lesion

Dieulafoy lesion is an enlarging arteriole, convoluted, and may cause erosion or bleeding. This lesion can be found in gaster or small intestine. Lesion in the small intestine is usually found in young age below 40 year old. Before the invention of enteroscopy, to diagnose this lesion, angiography or intraoperative endoscopy is needed.<sup>1</sup>

### DOUBLE BALLOON ENTEROSCOPY

Double balloon enteroscopy (DBE) is initially introduced in response to the difficulty in using push enteroscopy (PE) in evaluating gastrointestinal tract below Treitz ligament. This tool is an endoscopy set which consist of 200 cm enteroscope and 140 cm length overtube which is equipped with balloon at each ends. The inflated over tube balloon will hold intestinal wall, thus enteroscope can be inserted deeper. Further, enteroscope balloon is also inflated to resist the intestinal wall, therefore over tube can go through following enteroscope. Schematic pictures on the mechanism of action of DBE can be seen in Figure 1. In this way, the entire small intestine can be explored by enteroscope. DBE does not only play role in diagnostic, because several therapeutic procedures, including haemostatic clip, coagulation, or resection can be performed through the equipment which is inserted through the scope.<sup>4</sup>

This tool can be used in oral or even rectal approach. However, in searching the cause of OGIB, where most lesions are found in proximal region of the small intestine, oral approach is more beneficial. There is no specific preparation for DBE with oral approach, similarly with

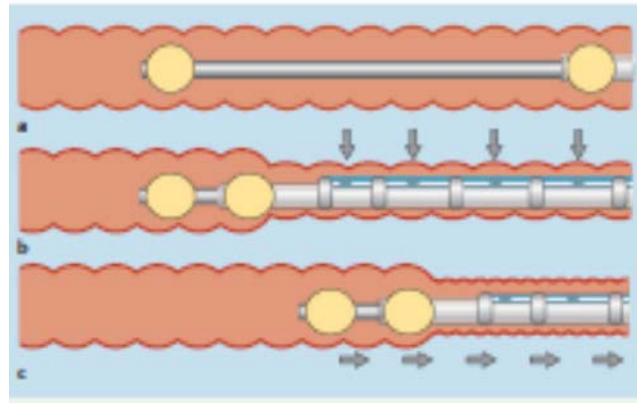


Figure 1. Scheme of mechanism of action of double balloon enteroscopy<sup>6</sup>

EGD. Meanwhile, rectal approach needs intestinal evacuation need to be performed to obtain good results. Several endoscopy centres use general anaesthesia in DBE procedure, however it is actually said that DBE is quite safe even if only using mild sedation.<sup>4</sup>

DBE is a quite safe procedure. DBE complications which may happen include perforation, bleeding, ileus, or pancreatitis. The incidence of pancreatitis post DBE is less than 1%, however in a cohort study by Pata et al, 6 from 48 (12.5%) patients which undergo DBE procedures per oral experience increase of amylase and lipase. This is associated with the duration of procedure and time between first and second balloon inflation. It is also stated that this incidence of pancreatitis decreases in line with the increased operator ability.<sup>4,7,8</sup>

The most common lesions being found in DBE examination include angioectasis, ulcer, and malignancy, similar to the picture in Figure 2. The weakness of this examination is the time needed to evaluate small intestine is quite long, in average 90-120 minutes is needed to complete one small intestine examination.<sup>7</sup>

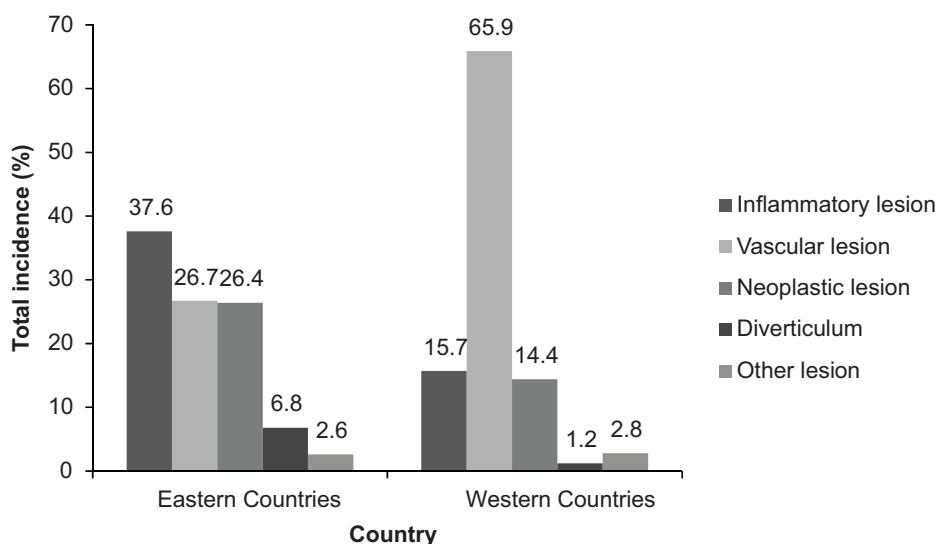


Figure 2. Common found lesion using double balloon enteroscopy<sup>7</sup>

## ROLE OF DOUBLE BALLOON ENTEROSCOPY IN DIAGNOSIS AND MANAGEMENT OF OBSCURE GASTROINTESTINAL BLEEDING

As has been explained previously that incident of OGIB is not so much, which is approximately 5% from all gastrointestinal tract bleeding. However, most bleeding source in OGIB originates from small intestine which cannot be reached using EGD or colonoscopy. Therefore, the role of diagnostic tool which allow total enteroscopy become important in diagnosing the cause of OGIB.

There were several algorithms which were proposed in determining the diagnosis of OGIB aetiology (Figure 3, 4, and 5). Nevertheless, clinical judgement based on anamnesis and physical examination on the suspected source of bleeding still become a key in guiding which examinations to be performed. In patient with severe recurrent hematochezia, without hypotension, we need to suspect the source of bleeding from the colon and colonoscopy can be repeated. Colon lesions which may lead to massive bleeding and stop by itself are diverticulosis or haemorrhoid. Similarly, if the complaint of recurrent melena, then EGD need to be repeated to re-evaluate oesophagus, gaster, and duodenum. After being certain that bleeding does not originate from upper or lower gastrointestinal tract, examinations can be focused on small intestine.<sup>1,9,10</sup>

Repeating EGD or colonoscopy in patients with OGIB is recommended, moreover if previous examination was performed with inadequate preparation. However, positive results are usually found in only 4-6% repeated examinations, while most bleeding source are still not found. Other modalities which can be used to explore further are push enteroscopy (PE), DBE, video capsule endoscopy (VCE), and radiology examinations.<sup>4,9</sup>

PE is upper gastrointestinal tract endoscopy with longer scope and may evaluate 50-60 cm deeper compared to usual EGD. With this tool, we can diagnose lesion until proximal jejunum. This tool is not using balloon like in the DBE.<sup>9</sup>

Meanwhile, VCE is one of the non-invasive procedures to know gastrointestinal intraluminal condition. Patient will be asked to swallow a pill containing camera which will record intraluminal pictures along the gastrointestinal tract. As a diagnostic modality, this tool is quite good and can be used to evaluate condition of the entire gastrointestinal, but not allowing therapeutic procedure to be performed. Therefore, if positive results were found in VCE examination, further invasive or semi-invasive

methods are required for treatment. In comparison to PE, VCE is more superior in diagnosing the source of gastrointestinal bleeding, particularly which originates from the small intestine. Therefore, prompt treatment can be administered. Contraindications of this examination include gastrointestinal obstruction, and need to be caution in those who use cardiac pacemaker. The weaknesses of VCE besides limited to diagnostic are quite common false positive results, low battery life which cause incomplete examination, and random passage which may miss the important lesions. Radiologic examinations such as barium enema, nuclear imaging, CT-Scan, or even angiography can be beneficial in several cases, but are less sensitive if compared to PE, DBE, or VCE.<sup>1,4,9</sup>

Currently, the quite good modalities in diagnosing the cause of OGIB are DBE and VCE. Several studies tried to compare which of these two examinations are better. Chen et al conducted a meta-analysis which compare VCE to DBE in diagnosing small intestine lesions. The results were DBE with combination of oral and rectal approach has similar or even better diagnostic value, compared to VCE. Which approach is to be taken, depends on patient's condition and the availability of the tools (Figure 6).<sup>11</sup> Meta-analysis study by Pasha et al, revealed that VCE was as good as DBE in diagnosing small intestine abnormality. However, they suggested VCE examinations to be performed first, if positive or negative results were obtained, but lesion was very much suspected to originate from small intestine, then DBE can be performed.<sup>12</sup> Relatively similar results were reported in a meta-analysis conducted by Teshima et al. DBE is not more inferior in comparison to VCE in diagnosing small intestine abnormality, and better results with DBE examination if previously the VCE result was positive.<sup>13</sup> Overall, DBE examination is more cost-effective compared to VCE which later need to be followed by further therapeutic procedures.<sup>9,11,12,13</sup>

Therapy in OGIB depends on the cause of bleeding. Lesion which is found through standard endoscopy can be managed by electrocautery, argon plasma coagulation, sclerosing injection, or mechanic haemostatic (clip or ligation). Similar to deeper lesions, therapy modalities being used are similar, but the tool being used is DBE or PE. Mass or tumour may be managed with collaboration with surgery department, while massive bleeding, may also need collaboration with surgery or interventional radiology department.<sup>9</sup>

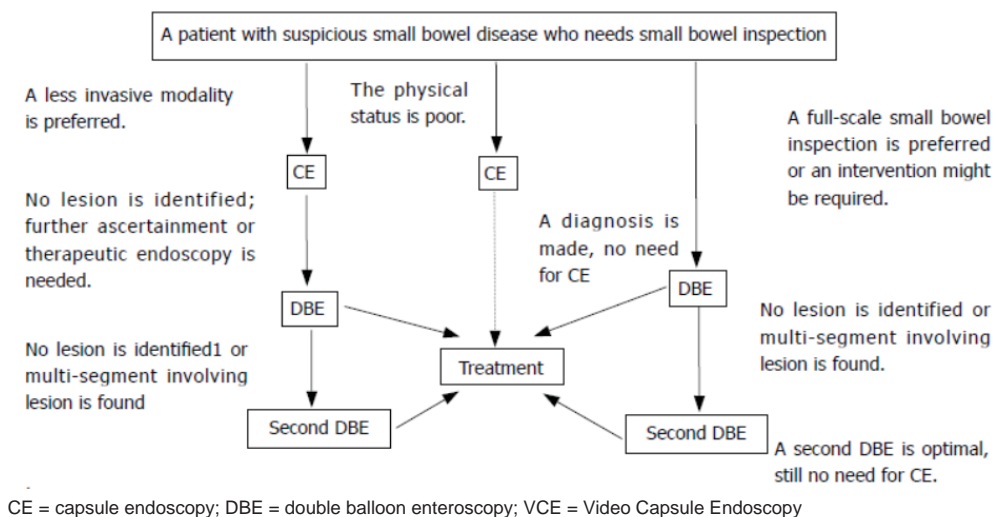


Figure 3. Diagnostic pathway in small intestine lesion using DBE and VCE<sup>11</sup>

## CONCLUSION

In patients with gastrointestinal bleeding, clinical approach through anamnesis and introduction of extra gastrointestinal signs have important value in determining further examinations to be performed.

Gastrointestinal bleeding which is most suspected to come from the gastrointestinal tract upper or lower, need to be further evaluated by using conventional endoscopy (EGD and colonoscopy) because may be missed in previous examinations due to less preparation or intermittent character of bleeding.

Bleeding which is not found after optimal conventional endoscopy is performed, it need to be suspected that the source is from small intestine. Two main modalities which can be used currently to evaluate it is VCE and DBE. These two examinations have diagnostic ability which is not significantly different, but may give out better results if both are used in combination. However, cost effectively, DBE without prior VCE is beneficial because therapy administration can be directly given in the abnormalities being found.

## REFERENCES

1. Savides TJ, Jansen DM. Gastrointestinal bleeding. In: Feldman M, Friedman LS, Brandt LJ, eds. Sleisenger and Fortrand's Gastrointestinal and Liver Disease. 9<sup>th</sup> ed. Philadelphia: Saunders Elsevier 2010.p.315-21.
2. Bresci G. Occult and obscure gastrointestinal bleeding: causes and diagnostic approach in 2009. World J Gastrointest Endosc 2009;1:3-6.
3. Greenwald DA. Obscure GI bleeding: which tests, how many, in what sequence?. ACG 2011:1-11.
4. Raju GS, Gerson L, Das A, Lewis B. American Gastroenterological Association (AGA) Institute technical review on obscure gastrointestinal bleeding. Gastroenterology 2007;133:1697-717.

5. Tacheci I, Kopacova M, Rejchrt S, Bures J. Review Article: non-steroidal anti inflammatory drug induced injury to the small intestine. Acta Medica 2010;53:3-11.
6. Ikeya K, Osawa S, Kuriyama S, Hamaya Y, Yamada T, Sugimoto M, et al. Decompression side tube-equipped double-balloon enteroscopy extends intubation depth and reduces patient discomfort. Endoscopy 2012;44:E256-7.
7. Xin L, Liao Z, Jiang YP, Li ZS. Indications, detectability, positive findings, total enteroscopy, and complications of diagnostic double-balloon enteroscopy: a systematic review of data over the first decade of use. Gastrointest Endosc 2011;74:563-70.
8. Pata C, Akyuz U, Erzin Y, Mutlu N, Mercan A, Dirican A. Post-procedure elevated amylase and lipase levels after double-balloon enteroscopy: relations with the double-balloon technique. Dig Dis Sci 2010;55:1982-8.
9. Fisher L, Krisky ML, Anderson MA, Appalaneni V, Benarjee S, Menachem TB, et al. The role of endoscopy in the management of obscure GI bleeding. Gastrointest Endosc 2010;72:471-9.
10. Liu K, Kaffes AJ. The diagnosis and investigation of obscure GI bleeding. Aliment Pharmacol Ther 2011;34:416-23.
11. Chen X, Ran ZH, Tong JL. A meta-analysis of the yield of capsule endoscopy compared to double-balloon enteroscopy in patients with small bowel diseases. World J Gastroenterol 2007;13:4372-8.
12. Pasha SF, Leighton JA, Das A, Harrison ME, Decker GA, Fleischer DE, et al. Double-balloon enteroscopy and capsule endoscopy have comparable diagnostic yield in small-bowel disease: a meta-analysis. Clin Gastroenterol Hepatol 2008;6:671-6.
13. Teshima CW, Kuipers EJ, Zanten SV, Mensink PBF. Double balloon enteroscopy and capsule endoscopy for obscure gastrointestinal bleeding: an updated meta-analysis. J Gastroenterol Hepatol 2011;26:796-801.

Correspondence  
 Dadang Makmun  
 Division of Gastroenterology  
 Department of Internal Medicine  
 Dr. Cipto Mangunkusumo Hospital  
 Jl. Diponegoro No. 71 Jakarta Indonesia  
 Phone: +62-21-3153957 Facsimile: +62-21-3142454  
 E-mail: hdmakmun@yahoo.com