

Unusual Case of Massive Obscure Gastrointestinal Bleeding: Ectopic Varices in Jejunum Caused by Arteriovenous Malformation

Hasan Maulahela, Kaka Renaldi, Ari Fahrial Syam

Division of Gastroenterology, Department of Internal Medicine,
Faculty of Medicine Universitas Indonesia/Dr. Cipto Mangunkusumo General National Hospital, Jakarta

Corresponding author:

Hasan Maulahela. Division of Gastroenterology, Department of Internal Medicine, Dr. Cipto Mangunkusumo National General Hospital. Jl. Diponegoro No. 71 Jakarta Indonesia. Phone: +62-21-3153957; facsimile: +62-21-3142454. Email: hasan.maulahela@yahoo.com

ABSTRACT

Small bowel ectopic varices is a rare etiology for obscure gastrointestinal bleeding. Ectopic varices in the absence of portal hypertension can be caused by congenital or familial conditions (e.g. malformation of vessel). Bleeding caused by ectopic varices can be massive and life threatening. Single Balloon Enteroscopy (SBE) is one of diagnostic modalities for obscure gastrointestinal bleeding. We report one case of obscure overt gastrointestinal bleeding with sub-acute onset. Previous esophagogastroduodenoscopy and colonoscopy cannot find the source of bleeding. On the enteroscopy we found varices at proximal jejunum with active bleeding during procedure. We applied hemostatic powder to stop the bleeding and proceed to surgery. Surgery was performed by enteroscopy guide. The jejunum section with varices was resected and the pathology confirmed the malformation of arteriovenous. Currently there is no available guideline or randomized study for the treatment of ectopic varices. Treatment options include ligation, sclerotherapy, surgery and interventional radiology. In this patient we choose surgery because of massive gastrointestinal bleeding.

Keywords: *Obscure gastrointestinal bleeding; single balloon enteroscopy; ectopic varices; arteriovenous malformation.*

ABSTRAK

Varises ektopik pada usus halus merupakan salah satu etiologi perdarahan saluran cerna yang jarang terjadi. Varises ektopik yang terjadi tanpa adanya hipertensi porta diakibatkan kelainan kongenital atau familial (misalnya malformasi pembuluh darah). Perdarahan varises ektopik dapat terjadi secara masif dan mengancam jiwa. Single Balloon Enteroscopy (SBE) merupakan salah satu modalitas untuk mencari sumber perdarahan apabila hasil pemeriksaan endoskopi saluran cerna atas dan bawah normal. Kami melaporkan kasus dengan perdarahan saluran cerna yang berlangsung sub-akut dimana sumber perdarahan tidak ditemukan dari pemeriksaan esofagogastroduodenoskopi dan kolonoskopi.

Kata kunci: *Perdarahan saluran cerna; enteroskopi; varises ektopik; malformasi arteriovenous.*

INTRODUCTION

Obscure gastrointestinal bleeding still remain a challenge in diagnosis and treatment. Diagnostic approach consists of video capsule endoscopy, enteroscopy, CT/MR enterography or angiography.¹ Enteroscopy is one of the modality for detecting etiology of obscure gastrointestinal bleeding. It allows therapeutic procedure simultaneously and assist the surgeon during operation.

Obscure gastrointestinal bleeding cause by ectopic varices is a rare disease. Ectopic varices can cause massive gastrointestinal bleeding with high mortality. Ectopic varices can occur in portal hypertension and in the absence of portal hypertension. In the absence of portal hypertension etiology of ectopic varices caused by congenital anomalous portosystemic anastomoses, abnormal vessel structures, arteriovenous fistulae, rare familial conditions, or related to thromboses²

This case report demonstrate the approach for obscure overt gastrointestinal bleeding and management of ectopic varices.

CASE ILLUSTRATION

Male 34 years old came to our hospital with bloody stool for 2 weeks before admission. Patient was weak and pale on admission. Patient didn't complain any abdominal pain or vomiting. No weight loss. On physical examination, we found pale conjunctiva and no abnormality in abdomen. Previously he had done colonoscopy but there was no clear source of bleeding.

Six months before patient also complaint black stool and received blood transfusion. From the previous esophagogastroduodenoscopy and colonoscopy also did not find any source of bleeding and the bleeding resolved itself. Laboratory findings show microcytic hypochromic anemia (Hb : 8.23 gr/dL) with normal hemostasis, viral marker (HbsAg and anti HCV) and tumor markers (CEA)

We decided to perform single balloon enteroscopy with antegrade approach to find the source of bleeding. From the enteroscopy we found the bleeding lesion in the jejunum (110 cm from incicivus) and the bleeding occur during enteroscopy. We apply hemostatic powder on the bleeding site for temporary hemostasis. During observation patient still have bleeding and we decided to refer patient to urgent surgery the next day.

During surgery we assist the surgeon to locate the varices using single balloon enteroscopy. The jejunum part with varices was resected and send to pathologist. The result was malformation of arteriovenosus. After surgery patient didn't complain any bleeding and the hemoglobin was stable.

DISCUSSION

The definition of obscure gastrointestinal bleeding is the absence of identified source of bleeding after normal upper endoscopy, colonoscopy, & small bowel radiographic evaluation. In updated definition this definition reserved for patient with bleeding despite video capsule endoscopy, deep enteroscopy, and CT enteroclysis/MR enteroclysis examination.¹ Obscure

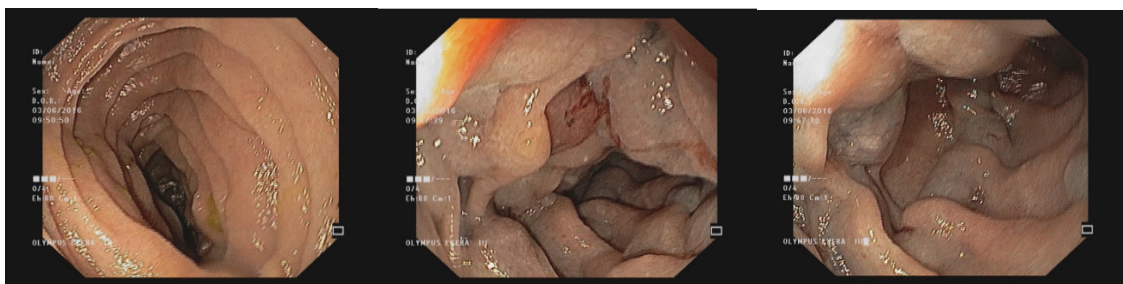


Figure 1. Single balloon enteroscopy finding of jejunal ectopic varices with point of bleeding

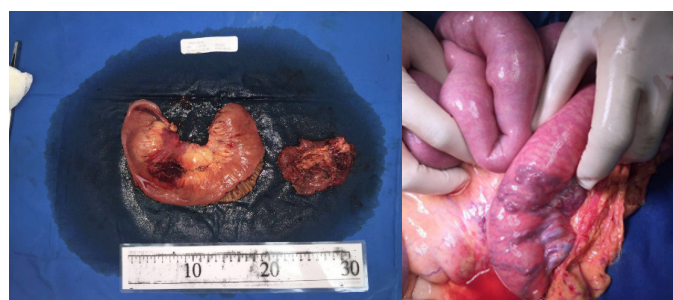


Figure 2. Resected part of jejunum with varices

gastrointestinal bleeding has been classified as obscure overt gastrointestinal bleeding if there is frank bleeding with or without iron deficiency and obscure occult bleeding if only guaiac test positive with iron deficiency. This patient had bloody stool with normal upper and lower endoscopy from other hospital so it is an obscure overt gastrointestinal bleeding. The prevalence for small bowel lesion as the etiology for gastrointestinal bleeding is around 5-10%.³

The approach for obscure gastrointestinal bleeding depends on the quantity of bleeding. Patient with subacute ongoing bleeding is best evaluated using deep enteroscopy to find source of bleeding. There are 3 types of deep enteroscopy that is: single-balloon enteroscopy (SBE) by Olympus, double-balloon enteroscopy (DBE) by Fujinon Inc. and spiral overtube enteroscopy. The diagnostic yield for SBE for patient with obscure gastrointestinal bleeding is about 47-77%.⁴⁻⁶

In our institution we use SBE and DBE. This patient directly underwent evaluation with SBE with antegrade approach. We found the lesion at 110 cm from incisivus which is in jejunum. The lesion appears as bluish submucosal vein enlargement with point of recent bleeding at the center. During enteroscopy there was active bleeding so we applied hemostatic powder.

Ectopic varices define as dilated portosystemic collateral veins located in unusual sites other than gastroesophageal region.⁷ Ectopic varices is rare cause of gastrointestinal bleeding. Approximately 5% of all variceal bleeding caused by ectopic varices. The mortality of ectopic variceal bleeding is high (up to 40%) because of massive bleeding at initial presentation.⁸ The most common site for ectopic varices is peristomal (26%), followed by duodenum (17%) and jejunum/ileum (17%).⁹ In the absence of portal hypertension the pathogenesis of ectopic varices is caused by anomalies of portal venous outflow, such as congenital anomalies or rare familial conditions.¹⁰ In this patient there were no sign of portal hypertension and the varices caused by congenital anomaly (malformation).

Management of ectopic varices depends on location, presentation, and local expertise. There are no guidelines or randomized trial for management of ectopic varices. Most publications come from case report or case series. In this patient because of massive bleeding and the location in small bowel we choose to do surgical resection of the affected area. Other modalities for ectopic varices are ligation, sclerotherapy or radiology intervention.²

REFERENCES

1. Gerson LB, Fidler JL, Cave DR, Leighton JA. ACG Clinical Guideline: Diagnosis and Management of Small Bowel Bleeding. *The American journal of gastroenterology*. 2015;110(9):1265-87; quiz 88.
2. Akhter NM, Haskal ZJ. Diagnosis and management of ectopic varices. *Gastrointestinal Intervention*. 2012;1(1):3-10.
3. Longstreth GF. Epidemiology and outcome of patients hospitalized with acute lower gastrointestinal hemorrhage: a population-based study. *The American journal of gastroenterology*. 1997;92(3):419-24.
4. Upchurch BR, Sanaka MR, Lopez AR, Vargo JJ. The clinical utility of single-balloon enteroscopy: a single-center experience of 172 procedures. *Gastrointestinal endoscopy*. 2010;71(7):1218-23.
5. Frantz DJ, Dellon ES, Grimm IS, Morgan DR. Single-balloon enteroscopy: results from an initial experience at a U.S. tertiary-care center. *Gastrointestinal endoscopy*. 2010;72(2):422-6.
6. Ramchandani M, Reddy DN, Gupta R, Lakhtakia S, Tandan M, Rao GV, et al. Diagnostic yield and therapeutic impact of single-balloon enteroscopy: series of 106 cases. *J Gastroenterol Hepatol*. 2009;24(10):1631-8.
7. Helmy A, Al Kahtani K, Al Fadda M. Updates in the pathogenesis, diagnosis and management of ectopic varices. *Hepatology International*. 2008;2(3):322-34.
8. Khouqeer F, Morrow C, Jordan P. Duodenal varices as a cause of massive upper gastrointestinal bleeding. *Surgery*. 1987;102(3):548-52.
9. Norton ID, Andrews JC, Kamath PS. Management of ectopic varices. *Hepatology*. 1998;28(4):1154-8.
10. Iredale JP, Ridings P, McGinn FP, Arthur MJ. Familial and idiopathic colonic varices: an unusual cause of lower gastrointestinal haemorrhage. *Gut*. 1992;33(9):1285-8.