

# Acute Tuberculous Appendicitis with Intestinal Obstruction

Yongkie Iswandi Purnama\*, I Dewa Nyoman Wibawa\*\*

\*Department of Internal Medicine, Faculty of Medicine, Universitas Udayana/Sanglah General Hospital, Denpasar

\*\*Division of Gastroentero-hepatology  
Department of Internal Medicine, Faculty of Medicine, Universitas Udayana/Sanglah General Hospital, Denpasar

## Corresponding author:

Yongkie Iswandi Purnama. Department of Internal Medicine, Sanglah General Hospital. Jl. Kesehatan No. 1 Denpasar Indonesia. Phone: +62-361-246274; facsimile: +62-361-235982. E-mail: yongkieip@gmail.com

## ABSTRACT

*Tuberculosis (TB) can involve any organs. Tuberculous appendicitis is a rare case. Incidence of primary tuberculous appendicitis is 0.1-0.3% while incidence of secondary tuberculous appendicitis is 1.5-3%. Tuberculous appendicitis occurs in 0.08% of all appendectomy and 0.2% of all TB cases. We reported an acute tuberculous appendicitis with intestinal obstruction. Diagnosis was established based on histopathological findings. Treatments included appendectomy and first category of anti tuberculosis drugs (ATD) for 6 months. This case was reported to add our insight about possibility of TB as an etiology of many pathologic conditions in abdominal cavity.*

**Keywords:** acute appendicitis, tuberculosis, intestinal obstruction

## ABSTRAK

*Tuberkulosis (TB) dapat mengenai berbagai organ tubuh. Kasus apendisitis TB jarang terjadi. Insidens apendisitis TB primer sebesar 0,1-0,3% sedangkan insidens apendisitis TB sekunder sebesar 1,5-3%. Apendisitis TB terjadi sebanyak 0,08% dari seluruh tindakan apendektomi dan 0,2% dari seluruh kasus TB. Kami melaporkan sebuah kasus apendisitis TB akut dengan ileus obstruksi. Diagnosis dibuat berdasarkan histopatologi. Terapi mencakup apendektomi dan pemberian obat anti tuberkulosis (OAT) kategori 1 selama 6 bulan. Kasus ini dilaporkan untuk menambah wawasan kita mengenai kemungkinan TB sebagai etiologi dari berbagai keadaan patologis dalam rongga abdomen.*

**Kata kunci:** apendisitis akut, tuberkulosis, ileus obstruksi

## INTRODUCTION

Tuberculosis (TB) is known as “the great imitator” because it can imitate various other diseases and affecting many organs.<sup>1,2</sup> Based on organ involvement, TB cases can be divided to 2 groups, i.e: pulmonary TB and extrapulmonary tuberculosis (EPTB).<sup>3,4</sup> Extrapulmonary tuberculosis cases take 15-20% of all TB cases in immunocompetent patients and more

than 50% of all TB cases in patient with Human Immunodeficiency Virus (HIV) infection.<sup>2</sup> Lymph nodes and pleural tissue are most frequently affected in EPTB cases.<sup>2,5</sup>

In abdominal cavity, symptom of TB varies greatly and unspecified. Most of patients can be diagnosed only after undergoing laparotomy procedure due to acute abdominal condition.<sup>6</sup> In this case report tuberculous

appendicitis was diagnosed after laparotomy procedure and histopathology examination of appendix and mesenteric lymph node specimens.

Tuberculous appendicitis is a rare case. In a study of 140 patients who underwent appendectomy, only 1 case (0.7%) of appendicitis due to TB as its etiology, and it was just an incidental finding.<sup>7</sup> This case was reported because of the rarity of tuberculous appendicitis and to add our insight about possibility of TB as an etiology of many pathologic conditions in abdominal cavity.

## CASE ILLUSTRATION

A 19 years-old female came because of pain at her lower right abdominal quadrant since 4 days before. The pain was migrated from epigastric to lower right abdomen. Other symptoms were fever, anorexia, nausea, vomit, and constipation. There were no vaginal discharge and bleeding, nor menstrual disorder. She had contact history to pulmonary TB patient whom was her ex-boyfriend. She did not have history of losing body weight, prolonged cough, nor chronic disease. She also had no smoking habit.

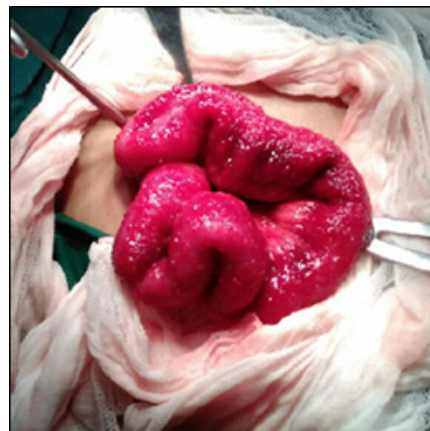
Physical examination found tachycardia, axilla temperature 38.5° C, increased bowel sound frequency, meteorismus, also tenderness and rebound tenderness at McBurney region. Complete blood count, blood chemistry, and urinalysis was normal; pregnancy test was negative. Abdominal plain X-ray and ultrasound revealed increasing intestinal air. Chest X-ray was normal.

She was diagnosed with acute appendicitis based on Alvarado (MANTRELS) score, which was 7 and then underwent urgent appendectomy. The surgery revealed sign of appendicitis, speckled reddish ileum (Figure 1), and lymph node involvement at mesentery. On the 3<sup>rd</sup> day after surgery she still felt pain with more distended abdomen and increased bowel sound. Three positions abdominal plain X-ray revealed intestinal obstruction so that decompression was done by putting in naso-gastric tube (NGT).

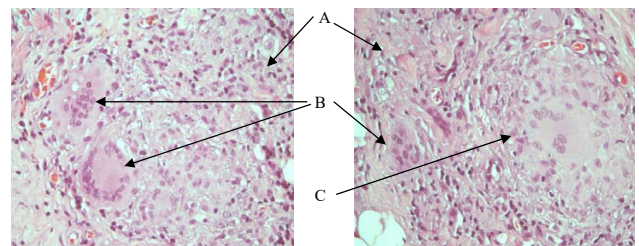
Histopathology examination of the appendix (Figure 2) and mesenteric node specimens (Figure 3) revealed diffuse distribution of lymphocytes, plasma cells, and epithelioid histiocyte which partially form the granuloma structure. In the mesenteric node specimens there were also multinucleated giant cell Langhans type and necrosis area. Based on these histopathological findings, it was concluded as chronic granulomatous inflammation at the mesenteric node and serosa of the appendix. Acid fast bacilli of her sputum was negative

for 3 times and anti-HIV serology was not reactive. Colonoscopy on the 13<sup>th</sup> day after surgery concluded normal findings from anal to terminal ileum (Figure 4).

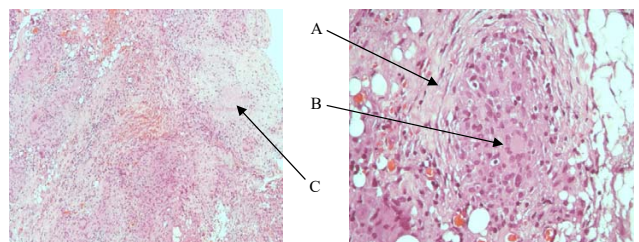
Final assessment were: acute tuberculous appendicitis with intestinal obstruction, and patient was treated with 1<sup>st</sup> category of anti tuberculosis drugs (ATD) which consists of: rifampicin 450 mg, isoniazid 225 mg, pyrazinamide 1200 mg, and ethambutol 825 mg daily. Patient's condition was improved and discharge on 17<sup>th</sup> day of hospitalization. Intensive phase of ATD was given for 2 months and continuous phase of ATD was given for 4 months.



**Figure 1. Macroscopic finding of patient's ileum: speckled reddish ileum**



**Figure 2. Histopathology of patient's appendix specimen: diffuse distribution of lymphocytes (A), plasma cells, and epithelioid histiocyte (B) which partially form the granuloma structure (C) (hematoxylin eosin stain, magnification 400x)**



**Figure 3. Histopathology of patient's mesenteric node specimen: granuloma structure (A), multinucleated giant cell Langhans type (B), and necrosis area (C) (hematoxylin eosin stain, magnification 100x and 400x)**

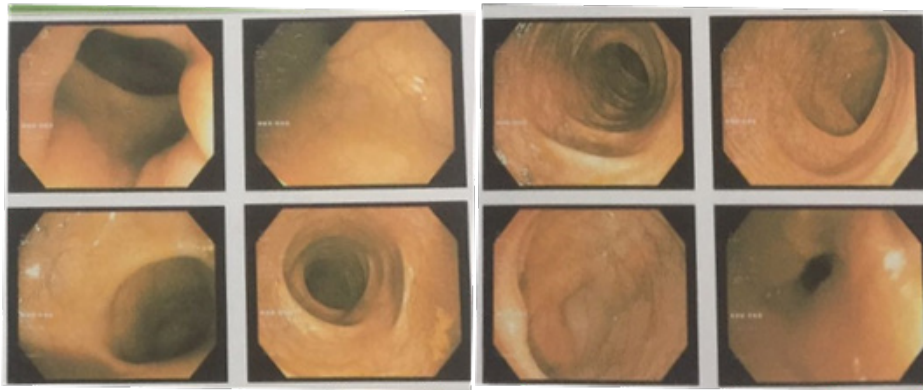


Figure 4. Colonoscopy result: normal

## DISCUSSION

Acute appendicitis (with any etiology) is the most common reason for doing emergency surgery. About 7% of population will suffer from appendicitis during someone's life. Peak incidence of appendicitis is between 21-30 years old. The risk of someone get an acute appendicitis is 8.6% for male and 6.7% for female.<sup>7,8,9</sup>

Acute inflammation of the appendix commonly precipitated by factors that increasing intraluminal pressure of appendix such as lymph hyperplasia, fecolith, tumor, parasite, fibrosis, and stricture. After the increasing of intraluminal pressure, lymph drainage will be blocked and thrombosis or vessel occlusion occurs. These condition will cause ischemia, necrosis, and bacterial overgrowth. In late stage the necrosis will be able to cause perforation.<sup>7,9,10</sup>

Tuberculous appendicitis first was reported by Corbin in 1873. It can be primary or secondary condition because of the spreading from another organ. Primary tuberculous appendicitis has incidence 0.1-0.3% while the secondary one (commonly spreading from ileocaecal TB) has incidence 1.5-3%.<sup>7,11,12</sup> Tuberculous appendicitis occurs in 0.08% of all appendectomy and 0.2% of all TB cases. This tuberculous appendicitis is also rare even in country where TB infection is still be the major public health problem.<sup>13</sup> Risk factors of gastrointestinal TB are: history of tight contact with active pulmonary TB patient, HIV infection, alcoholism, intravenous drug abuse, homeless people, low income, bad environmental sanitation, and health workers.<sup>14</sup> In this reported case the risk factor was tight contact with active pulmonary TB patient.

As the World Health Organization (WHO) guideline, EPTB diagnosis can be established based on: positive specimen culture of TB or histopathological findings of TB infection or strong clinical evidence which is consistent with active EPTB.<sup>3</sup> In this reported case the diagnosis was established based on histopathological

findings. The specific histopathological feature in tissue affected TB is chronic granulomatous inflammation which consists of epithelioid macrophage surrounded by lymphocytes, plasma cells, fibrosis in varied degrees, Langhans cells (multinucleated giant cells), and caseosa necrosis in the middle of granuloma. Caseosa necrosis is a very important criteria for diagnosing intestinal TB. These findings have high specificity and can be used for making decision to start ATD treatment.<sup>1,4,15,16</sup>

As much as 75% gastrointestinal TB occurs at ileocaecal. Other locations of gastrointestinal tract which can be involved by TB, respectively from the most common, are: ascending colon, jejunum, appendix, duodenum, gaster, esophagus, sigmoid colon, and rectum. It is possible that TB occurs at several locations along gastrointestinal tract in the same time.<sup>3,14,15,17,18</sup> The rarity of primary tuberculous appendicitis may be due to the fact that there is minimal contact of appendicular mucosa with intestinal contents.<sup>12</sup> Etiopathology classification of tuberculous appendicitis are: (1) Secondary tuberculous appendicitis: a) Local extension of ileocaecal TB, b) Retrograde lymphatic spread from distant lesions in the ileum or ascending colon, c) Appendicular serositis/periappendicitis in peritoneal TB cases; (2) Primary tuberculous appendicitis due to direct contact with infected intestinal contents or haematogenous spread from a distant focus which is not clinically detectable.<sup>19</sup>

There are 3 types of tuberculous appendicitis clinical presentation, i.e: (1) Chronic disease with mild to moderate intermittent right iliac fossa pain associated with vomiting and diarrhoea indistinguishable from ileocaecal TB; (2) Acute obstructive appendicitis. This acute type is usually indistinguishable from severe pyogenic infection which superimposed with tuberculous appendicitis; (3) Latent type discovered incidentally.<sup>11,12,19,20</sup> In this reported case the patient had tuberculous appendicitis with acute manifestation and intestinal obstruction.

Intestinal obstruction in tuberculous appendicitis can happen due to the inflammation process which blocks the terminal ileum lumen and forms adhesion. The migration of omentum to the right iliac fossa in acute appendicitis can cause kinking of the bowel.<sup>21,22</sup> Obstruction can also be caused by TB pathogenesis in gastrointestinal tract. Gastrointestinal TB, including tuberculous appendicitis, can manifest as ulceratif, hyperplastic, or ulcero-hyperplastic lesions. In ulceratif lesion there can be bleeding, perforation, and fistula while in hyperplastic lesion there can be mass or causing obstruction.<sup>11,23</sup>

Therapy of gastrointestinal TB is not different from pulmonary TB.<sup>4,15,24</sup> Standard ATD consists of 4 drugs, i.e: isoniazid 5 mg/kg of body weight daily, rifampicin 10 mg/kg of body weight daily, pyrazinamide 30 mg/kg of body weight daily, dan ethambutol 20 mg/kg of body weight daily, which taken for 2 months, then continued by isoniazid and rifampicin for 4 months.<sup>4,11,24</sup> As in this reported case, in addition to ATD, appendectomy must be performed as the initial therapy in acute tuberculous appendicitis case.<sup>13,17</sup>

Delayed in diagnosis and therapy of gastrointestinal TB can be fatal if there are perforation and peritonitis.<sup>7,13,24</sup> In addition to perforation and peritonitis, the gastrointestinal TB complications also can be: obstruction, malabsorption, gastrointestinal bleeding, and fistula forming.<sup>3</sup> Female who suffered from an appendicitis perforation can cause infertility in her future.<sup>7</sup>

## REFERENCES

- Gonzalez FPC, Romero AZR, Rivas CMW, Reyes DPA, Arismendi MGJ. Fibroadhesive peritoneal tuberculosis mimicking inflammatory acute abdomen due to appendiceal adhesions. *Revista de Gastroenterologia de Mexico* 2016;x:1-3.
- Jetley S, Jairajpuri ZS, Pujani M, Khan S, Rana S. Tuberculosis 'the great imitator': a usual disease with unusual presentations. *Indian J Tuberc* 2017;64:54-9.
- Norbis L, Alagna R, Tortoli E, Codecasa LR, Migliori GB, Cirillo DM. Challenges and perspectives in the diagnosis of extrapulmonary tuberculosis. *Expert Rev Anti Infect Ther* 2014;12:633-47.
- Lapausa MR, Saldana AM, Asensio AN. Extrapulmonary tuberculosis: an overview. *Rev Esp Sanid Penit* 2015;17:3-11.
- Anand P, Sushmita C. Isolated mesenteric tuberculosis presented as abdominal mass. *Nat J Med Res* 2012;2:389-90.
- Mukhopadhyay A, Dey R, Bhattacharya U. Abdominal tuberculosis with an acute abdomen: our clinical experience. *J Clin Diagn Res* 2014;8:NC07-NC09.
- Sinha RTK, Dey A. A retrospective study of histopathological features of appendectomy specimens – what all can expect? *J Med Sci Health* 2016;2:6-12.
- Zimmermann A. Appendicitis: histopathology and classification. *Progress in Surgery* 1998;25:18-26.
- Minocha A. *Handbook of Digestive Diseases*. USA: Slack Incorporated; 2004.p.279-81.
- Dasanayake DLP, Wijetunge S, Dharani K, Bowala DNK, Ratnatunga NVI. Unexpected pathological lesions of appendix: an analysis of 3000 surgical specimens from Sri Lanka. *Sri Lanka J Med* 2015;24:4-11.
- Chandra BJS, Girish TU, Thrishuli PB, Vinay HG. Primary tuberculosis of the appendix: a rare cause of a common disease. *J Surg Tech Case Rep* 2013;5:32-4.
- Tauro LF, Aithala PS, George SRC, Hanumanthappa, Martis J. Primary tuberculosis of the appendix. *Oman Med J* 2010;25:257-8.
- Chong VH, Telisinghe PU, Yapp SKS, Chong CF. Tuberculous appendix: a review of clinical presentations and outcomes. *Singapore Med J* 2011;52:90-3.
- Gan H, Mely M, Zhao J, Zhu L. An analysis of the clinical, endoscopic, and pathologic features of intestinal tuberculosis. *J Clin Gastroenterol* 2016;50:470-5.
- Rathi P, Gambhire P. Abdominal tuberculosis. *J Assoc Physicians India* 2016;64:38-47.
- Debi U, Ravisankar V, Prasad KK, Sinha SK, Sharma AK. Abdominal tuberculosis of the gastrointestinal tract: revisited. *World J Gastroenterol* 2014;20:14831-40.
- Constantinescu C, Vayalumkal J, Fisher D. An unusual case of appendicitis. *CMAJ* 2014;186:1241-3.
- Raviglione MC. Tuberculosis. In: Kasper DL, Fauci AS, Hauser SL, Longo DL, Jameson JL, Loscalzo J, eds. *Harrison's Principles of Internal Medicine*, 19<sup>th</sup> ed. New York: McGraw-Hill Companies 2005.p.1102-22.
- Singh MK, Arunabh, Kapoor VK. Tuberculosis of the appendix – a report of 17 cases and a suggested aetiopathological classification. *Postgrad Med J* 1987;63:855-7.
- Gill M, Lal S, Chandna A, Jain D, Sen R, Gupta S. Isolated tuberculous appendix presenting as acute abdominal emergency – a rare case report. *SEAJCRR* 2015;4:1353-7.
- Harrison S, Mahawar K, Brown D, Boobis L, Small P. Acute appendicitis presenting as small bowel obstruction: two case reports. *Cases Journal* 2009;2:9106.
- Maly O, Paral J. Appendicitis as a rare cause of mechanical small-bowel obstruction: a literature review of case reports. *Int J Surg Case Rep* 2016;29:180-4.
- Kuntanapreeda K. Tuberculous appendicitis presenting with lower gastrointestinal hemorrhage – a case report and review of the literature. *J Med Assoc Thai* 2008;91:937-42.
- Houston A, Macallan DC. Extrapulmonary tuberculosis. *Medicine* 2014;42:18-22.