

# The Management Problems of Patient with Chronic Hepatitis B Infection and Its Reactivation

Tri Asih Imro'ati\*, Ummi Mainunah\*\*

\*Department of Internal Medicine, Faculty of Medicine

Universitas Airlangga/Dr. Soetomo General Hospital, Surabaya

\*\*Division of Gastroentero-hepatology, Department of Internal Medicine

Faculty of Medicine, Universitas Airlangga/Dr. Soetomo General Hospital, Surabaya

## Corresponding author:

Ummi Maimunah. Division of Gastroentero-hepatology, Department of Internal Medicine, Universitas Airlangga/ Dr. Soetomo Hospital. Jl Mayjend Prof Dr Moestopo No. 6-8 Surabaya Indonesia. Phone +62-31-5501614; Facsimile: +62-31-5023865. E-mail: ummima@gmail.com.

## ABSTRACT

Hepatitis B virus (HBV) infection is a major global health problem in the world and particularly in Indonesia. It can cause chronic infection and puts people at high risk of death from cirrhosis and liver cancer. In this case, we will show about the problems that may occur while we manage a patient. A 55 years old man with chronic hepatitis B has been treated with Telbivudin 600 mg for 8 years and then stop for 2 years (The hepatitis B surface antigen/HBsAg has been non reactive, hepatitis B e antigen (HBeAg) has been seroconversion from positive to negative, and HBV deoxyribonucleic acid (DNA) has been not detected since 2014 until January 2016). In 2018, patients undergo surgery to remove nodules in the liver. After that, there were transaminase and bilirubin elevation, and then hepatitis B surface antigen (HBsAg) become reactive again. After giving combination therapy of Telbivudin 600 mg with Entecavir 0.5 mg and metyl prednisolone 8 mg (per os, three times a day) for 1 months, the transaminase became decrease, but the bilirubine was still high. The patient was reported to have died in February 2019 after being hospitalized in a hospital outside Java, so we could not know or investigasted the cause of his mortality.

**Keywords:** chronic hepatitis B, reactivation

## ABSTRAK

Infeksi virus hepatitis B adalah masalah kesehatan global utama di dunia dan khususnya di Indonesia. Penyakit ini dapat menyebabkan infeksi kronis dan menempatkan orang pada risiko tinggi kematian akibat sirosis dan kanker hati. Dalam hal ini, kami akan menunjukkan tentang masalah yang mungkin terjadi saat kita mengelola pasien. Seorang pria berusia 55 tahun dengan hepatitis B kronis telah diobati dengan Telbivudin 600 mg selama 8 tahun dan kemudian berhenti selama 2 tahun (hepatitis B surface antigen/HBsAg tidak reaktif, hepatitis B e antigen/HBeAg telah serokonversi dari positif ke negatif, dan deoxyribonucleic acid (DNA) hepatitis b virus (HBV) tidak terdeteksi. sejak 2014 hingga Januari 2016). Pada tahun 2018 pasien menjalani operasi pengangkatan nodul pada liver; setelah itu, terjadi peningkatan transaminase dan bilirubin, kemudian HBsAg menjadi reaktif kemlagi. Setelah memberikan terapi kombinasi Telbivudin 600 mg dengan Entecavir 0,5 mg dan metil prednisolon 3x8 mg per oral selama 1 bulan, transaminase membaik, tetapi bilirubine masih tinggi. Pasien dilaporkan meninggal di rumah pada Februari 2019 setelah menjalani rawat inap di rumah sakit di luar Jawa, sehingga kita tidak mengetahui penyebab kematiannya.

**Kata kunci:** hepatitis B kronik, reaktifasi

## INTRODUCTION

Hepatitis B virus infection is a major global health problem in the world and particularly in Indonesia. In Indonesia, hepatitis B sufferers in healthy populations are about 4-20.3%. It can cause chronic infection and puts people at high risk of death from cirrhosis and liver cancer. In 2015, hepatitis B resulted in 887,000 deaths, mostly from complications (including cirrhosis and hepatocellular carcinoma).<sup>1,2</sup>

Hepatitis B virus infection can give two clinical outcomes, namely acute hepatitis and chronic hepatitis. Acute hepatitis B infection can resolve spontaneously and make antibody to this infection, while chronic hepatitis B infection have four phases (immune tolerance, immune clearance, inactive sufferer, and reactivation phase).<sup>1</sup> Hepatitis B virus (HBV) may persist in the blood for decades after clinical recovery from acute hepatitis despite the presence of serum antibodies. Immunosuppressive conditions or drugs may allow dormant HBV to flare or reactivate. Additionally, genetic factors (eg, genetic mutations) may influence the risk for reactivation by affecting hepatitis B core antibody (anti-HBc) response.<sup>3</sup>

The primary treatment goals for patients with hepatitis B (HBV) infection are to prevent progression of the disease, particularly to cirrhosis, liver failure, and hepatocellular carcinoma. A synergistic approach of suppressing viral load and boosting the patient's immune response with immunotherapeutic interventions is needed for the best prognosis. The prevention of hepatocellular carcinoma (HCC) often includes the use of antiviral treatment using pegylated interferon (PEG-IFN) or nucleos(t)ide analogues. Therapy is currently recommended for patients with evidence of chronic active hepatitis B disease (ie, abnormal aminotransferase levels, positive HBV deoxyribonucleic acid (DNA) findings, positive or negative hepatitis B e antigen [HBeAg]).<sup>3</sup> This case will show the management problems of patient with chronic hepatitis B and its reactivation.

## CASE ILLUSTRATION

A 55 years old man with chronic hepatitis B has been treated with Telbivudin 600 mg for 8 years (2008-2016) and then stop at January 2016 for 2 years (The HBsAg has been non reactive, HBeAg has been seroconversion from positive to negative, and HBV DNA has been not detected since 2014 until January 2016). There were no history of hypertension, diabetes mellitus, cardiovascular diseases, or alcohol intake.

There are transaminase elevation and bilirubin; HBsAg become reactive again at Desember 2018 after the patient has undergone surgery (resection) to remove the nodules in the liver. Clinical findings/ investigations are: body mass index (BMI) 24 kg/m<sup>2</sup>, General weakness, ECOG 1, vital sign within normal limit, icteric.

The last laboratorium findings are: hemoglobin (Hb) 13.5 g/dL; leucocyte 5580/mm<sup>3</sup>; platelet 183,000/mm<sup>3</sup>; aspartate aminotransferase (AST) 131 U/L (from 2210.5) ; alanine aminotransferase (ALT) 152 U/L (from 1362); total bilirubin 26.1 mg/dL (from 16.4); direct bilirubin 16.56 mg/dL (from 14.29); albumin 2.84 g/dL; random blood glucose 77 mg/dL; sodium 132 meq/L; potassium 3.4 meq/L; chloride 101 meq/L; blood urea nitrogen (BUN) 19.7 mg/dL; creatinin serum 1.22 ng/dL; PPT 28.4 (Control: 10.8-14.4 second); activated partial thromboplastin time/APTT 62.3 (Control: 24-36 second); international normalized ratio (INR) 2.82; HBsAg positive: 39 IU/mL (after 2 years non reactive); AntiHBe reactive; HBeAg non reactive; IgM antiHAV non reactive; Anti HCV non reactive; carcinoembryonic antigen (CEA) 2.7 ng/mL; alpha-fetoprotein (AFP) 157.1 ng/mL; Ca19-9 1299 ng/mL.

The electrocardiogram was sinus rhythm 71 times per minute. The chest X- ray was within normal limit. The abdominal CT-scan 3 phase (October 2018) showed benign scar tissue at segmen VII of the liver (diameter 2.3 cm), benign small calcified lesion at subcutaneous under manubrium of stern, and no abnormalities in another abdominal organs. The abdominal MRI (December 2018) showed a nodul at segmen VII in the liver with 27.7 x 28.5 mm size (suspected malignancy), no ascites, no abnormalities in spleen, gall bladder, pancreas and gastrointestinal tract. The post resection abdominal ultrasonogram (Desember 2018) showed chronic parenchymal liver disease, no residive mass in the liver, there was minimally bilateral pleural effusion, and no abnormalities in the pancreas, gall bladder, spleen, renal, bladder, and prostat.

The clinical problems/questions are : (1) How can we explain these phenomenon?; (2) Is it reactivation/ flare?; (3) After we give combination therapy of Telbivudin 600 mg with Entecavir 0.5 mg for 4 months, the transaminase became decrease, but the bilirubine was become more higher; what happened to this patient?

Unfortunately, the patient was reported by his family, died 1 in February 2019 after being hospitalized in a hospital outside Java.

## DISCUSSION

The criteria of chronic hepatitis B infection are: (1) HBsAg seropositive for more than 6 months; (2) HBV-DNA serum > 20.000 IU/mL (2000-20.000 IU/mL for HBeAg negative); (3) Persistent/intermittent ALT elevation; (4) liver biopsy reveals chronic hepatitis with moderate to severe necroinflammation.<sup>1</sup>

This patient has HBsAg reactive since 2002, and still reactive at 2004; the HBeAg was positive with intermittent elevation of alanine aminotransferase (ALT); the HBV-DNA was elevated from < 357 IU/mL to >25 million IU/mL at 2007; but there was no data about liver biopsy.

The Indonesian Association for the Study of the Liver (Ina ASL) has give recommendation about the aim and therapeutic target for chronic hepatitis B. The aims of therapy are to improve the quality of life and patient's survival by the prevention of disease progressivity, cirrhosis, decompensated cirrhosis, end state liver disease, hepatocellular carcinoma, and mortality; at once to prevent of viral transmission. The ideal endpoint of hepatitis B therapy is HBsAg loss with/without seroconversion of antiHBs.<sup>1</sup>

This patient has achieve HBsAg nonreactive after take entecavir 0,5 mg since 2008 and replace with telbivudine 600 mg since 2009, because entecavir didn't available at that moment. The HBeAg has been seroconversion from positive to negative, and HBV DNA has been not detected since 2014 until Jan 2016.

The indications of therapy in hepatitis B infection depend on: (1) HBV DNA serum level; (2) HBeAg status; (3) ALT level; (4) liver histological findings. The treatment indication of chronic hepatitis B patient with non cirrhotic HBeAg positive can be seen at figure 1 below.<sup>1</sup>

The gold standard examination to determine the degree of liver fibrosis is a liver biopsy, but this procedure is invasive, and has known adverse events and limitations. For noninvasive (indirect) examinations are positron emission tomography, ultrasonography, elastography and magnetic resonance imaging (MRI), but require high costs. The simple, available, inexpensive and accurate noninvasive examination is the aminotransferase to platelet ratio index (APRI) score which can be calculated by the following formula (value ≥1.5 indicates significant fibrosis):<sup>4</sup>

$$APRI = \frac{\frac{AST \text{ level}}{ULN *}}{\text{Platelet counts } (10^9 / L)} \times 100$$

\*ULN: upper limit normal

This patient has HBV DNA level >25.10<sup>6</sup> IU/mL at 2007, HBeAg reactive, and intermittent elevation of ALT (since 2004) between 17.3 to 833.6 U/l, but there was no data about liver biopsy. APRI score was 5.782. The ultrasonogram showed chronic parenchymal liver disease.

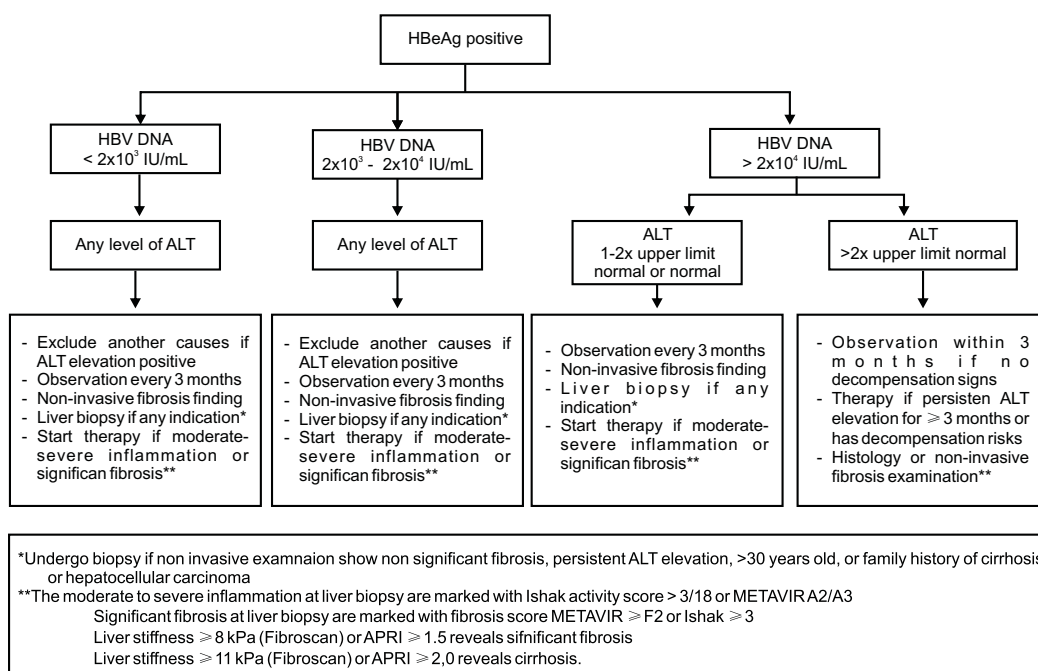


Figure 1. The treatment indications of chronic hepatitis B patient with non-cirrhotic HBeAg positive<sup>1</sup>

The drugs of choice for treatment of chronic hepatitis B are interferon base (pegylated interferon  $\alpha$ -2a 90-180  $\mu$ g once a week, or pegylated interferon  $\alpha$ -2b 1-1.5  $\mu$ g/kg once a week) and nucleos(t)ide analog base. The nucleos(t)ide analog base includes lamivudine 100 mg, adefovir 10 mg, entecavir 0,5 mg, telbivudin 600 mg, and tenofovir 300 mg. Tenofovir 300 mg once a day or entecavir 0,5 mg once a day is the first line for therapy with nucleoside analog. The second line drugs can be given depend on drug availability or urgent treatment at naïve patients or unknown resistency profile, include of lamivudine 100 mg once a day, adefovir 10 mg once a day, or telbivudin 600 mg once a day.<sup>1</sup>

This patient has take entecavir 0,5 mg once a day for 6 months, after that was given telbivudine 600 mg once a day (2009 to 2016) due to the unavailability of entecavir at that moment.

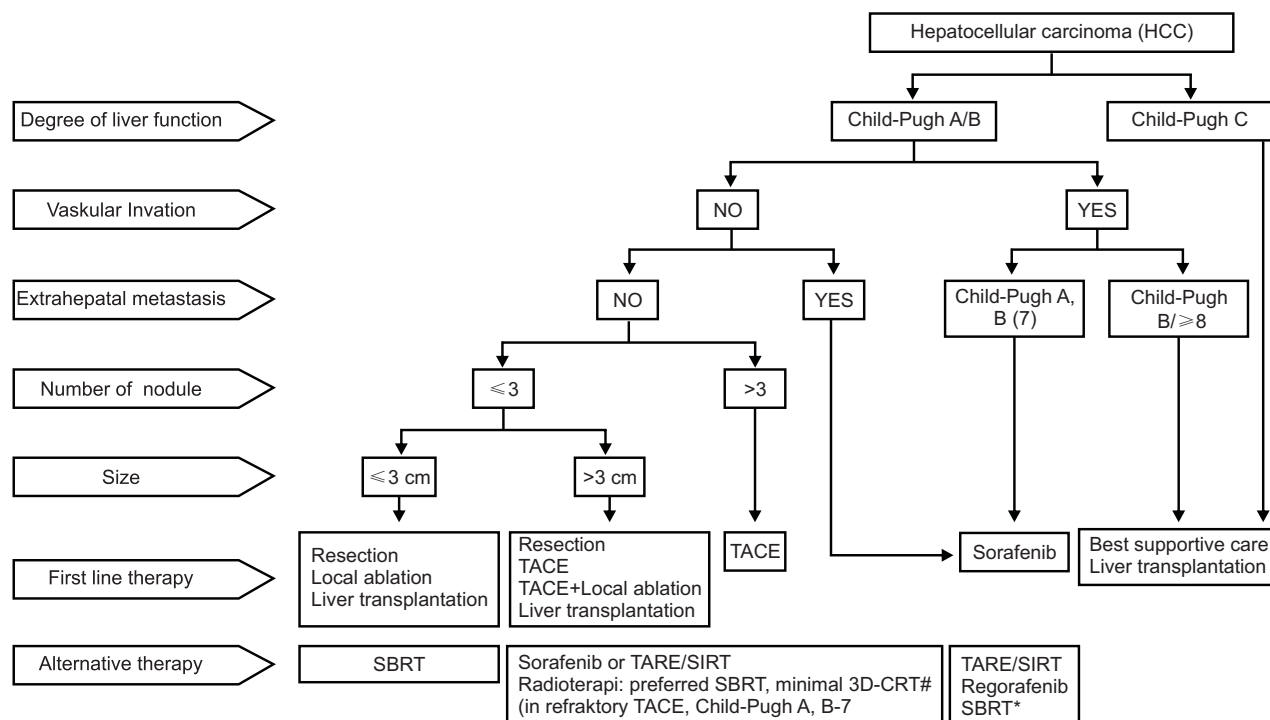
The termination therapy of nucleos(t)ide analog base on PPHI recommendation are: (1) Seroconversion HBeAg with HBV DNA undetected for at least 12 months at patients with non-cirrhosis HBeAg positive; (2) For cirrhotic patients with HBeAg positive that has achieve HBeAg seroconversion should continue the treatment for a lifetime; (3) For non-cirrhotic patients with HBeAg negative, the treatment can be terminated if HBsAg loss; (4) For cirrhotic patients with HBeAg

negative, treatment should continue for a lifetime.<sup>1</sup>

The laboratorium evaluation of HBeAg, ALT, and HBV DNA should be obtained every month at the first 3 months after treatment has stopped. After that, should be continue every 3 months for a year. If no relapse, the evaluation should be obtained every 3 months at cirrhotic patients, and every 6 months at non-cirrhotic patients.<sup>1</sup>

This patients has terminate treatment from 2016 based on HBsAg was non reactive, HBeAg become negative, HBV DNA not detected, and antiHBc non-reactive since 2014 until August 2018 (the evaluation of these markers was every 6 months), even though according to the guidelines it should continue for a lifetime because the APRI score showed significant fibrosis.

HCC is the second most common cause of cancer deaths worldwide and is the most common cancer in men and the ninth most in women (male to female ratio 2-4:1), with a greater ratio in regions with a high prevalence of HCC risk factors. Approximately 70-90% of HCC patients have risk factors in the form of liver disease and liver cirrhosis, with the most risk factors being hepatitis B virus, hepatitis C virus, alcoholic liver disease and non-alcoholic steatohepatitis (NASH). Management of HCC can be seen in Figure 2 below.<sup>5</sup>



SBRT: stereotactic body radiation therapy, SIRT: selective internal radiation therapy, TACE: transarterial chemoembolization, TARE: tranarterial radioembolization, \*SBRT: in HCC with portal vein thrombus that no other therapy can do, size < 8 cm, Child-Pugh A. #: radiotherapy is given in combination with TACE or if it fails with TACE.

Figure 2. The algorithm of hepatocellular carcinoma (HCC) management<sup>5</sup>

**Table 1. Antiviral options for management of antiviral resistance**

Antiviral resistance by genotypic testing	Switch strategy (preferred)	Add strategy: 2 Drugs without cross-resistance
Lamivudine resistance	Tenofovir* (tenofovir disoproxil fumarate/TDF or tenofovir alafenamide/TAF)	Continue lamivudine; add tenofovir (TDF or TAF) (or alternative emtricitabine-tenofovir)
Telbivudine resistance	Tenofovir* (TDF or TAF)	Continue telbivudine; add tenofovir (TDF or TAF)
Adefovir resistance	Entecavir or Tenofovir* (TDF or TAF)	Continue adefovir; add entecavir
Entecavir resistance	Tenofovir* (TDF or TAF)	Continue entecavir; add tenofovir (TDF or TAF) or alternative emtricitabine-tenofovir
Tenofovir resistance	Entecavir*	Continue tenofovir (TDF or TAF) and add entecavir
Multidrug resistance	Tenofovir	Combined tenofovir (TDF or TAF) and entecavir*

\*Efficacy similar between switching to an antiviral with high genetic barrier to resistance and adding 2 drugs without cross-resistance with follow-up to 5 years. Thus, switching is the preferred strategy except if HBV is multidrug resistant

Hepatitis B reactivation is a clinical problem with high morbidity and mortality. This is very common in individuals with suppressed immune conditions, although it can also occur spontaneously. Individuals who have malignancies and chronic hepatitis B have a high risk of HBV reactivation, especially if they undergo a chemotherapy procedure. The mechanism underlying reactivation is the loss of immune control over HBV replication in hepatocytes. Hepatitis B reactivation clinically varies from asymptomatic elevation of serum ALT to acute liver failure and death.<sup>6</sup> The occurrence of hepatitis B reactivation in HCC conditions is directly related to poor survival of HCC. To date, information on hepatitis B virus reactivation in negative HbsAg patients with HCC is limited to case reports or small case series.<sup>7</sup>

Jaundice in the reactivation of chronic hepatitis B carries a poor prognosis. A study of 46 severely reactivated patients with jaundice, a quarter of them died or needed a liver transplant.<sup>8</sup>

The use of steroids in severe viral hepatitis has not been widely studied. Research by Gregory et al suggest that the use of high-dose and fixed steroids in these patients appears to increase mortality and suggest corticosteroids are contraindicated in patients with severe viral hepatitis. Research by Ware et al shows a different thing where steroid complications are less frequent, possibly because they use high doses of prednisolone for a relatively short period of time and a rapid tapering off.<sup>9</sup>

Katz et al found the possibility that the effect of cortisone on bilirubinogenesis may play a role in the rapid drop of serum bilirubin in acute hepatitis.<sup>10</sup> Theoretically, corticosteroids could lower the serum bilirubin concentration of jaundiced patients by one or more of the following ways: (1) Increase the excretion of bilirubin into the bile; (2) Reverse or ameliorate the underlying disease process; (3) Promote the renal loss of bilirubin; (4) Change the apparent serum concentration of pigment by expanding plasma volume; (5) Favor the extravascular distribution of

bilirubin; (6) Alter the metabolic processes involved in the breakdown of heme or bilirubin.<sup>11</sup>

The American Association for the Study of Liver Diseases (AASLD) 2018 Hepatitis B Guidance said that Entecavir may be used in patients with adefovir- or tenofovir-resistant HBV, though confirmed cases of tenofovir resistance are notably extremely rare (see table 1). Entecavir should not be used in patients with lamivudine or telbivudine resistance, because the risk of subsequent entecavir resistance is high.<sup>12</sup>

After terminate the treatment for 2 years, there were transaminase and bilirubin elevation (ALT 1362,9 U/mL, direct bilirubin 14,29, and total bilirubin 16,4); HBsAg become reactive again at Des 2018. The patient (now in the Child-Pugh C classification) got in-hospitalization treatment until the ALT became 152 U/mL, but the direct and total bilirubin still high (16,56 and 9,54 mg/dL respectively), at 17 January 2019. At that moment, he take telbivudine 600 mg once a day, Entecavir 0,5 mg once a day (due to suspected resistance telbivudine while tenofovir did'nt available at that moment), and per os methyl prednisolone 8 mg three times a day for 1 month (tapered off) to decrease the bilirubinemia. Unfortunately, at February 2019, his family reported that the patient has passed away after being hospitalized in a hospital outside Java, so we could not know or investigated the cause of his mortality.

## REFERENCES

1. PPHI. Konsensus Nasional Penatalaksanaan Hepatitis B di Indonesia. PPHI 2017.
2. WHO, 2018. Hepatitis B. [serial online] [cited 2019 March 12]. Available from URL: <https://www.who.int/news-room/fact-sheets/detail/hepatitis-b>
3. Pypsovopoulos NT. Hepatitis B treatment and management. [serial online] [cited 2019 March 12]. Available from URL: <https://emedicine.medscape.com/article/177632-treatment>
4. Castillo AL, Pineda FP, Cardenas EO, Avila FS, Vorackova FV. AST to platelet ratio index (APRI) for the noninvasive evaluation of liver fibrosis. *Ann Hepatol* 2008;7:350-7.
5. PPHI. Konsensus Nasional Penatalaksanaan Karsinoma Sel Hati. PPHI 2017.

6. Kholili U, Yanti T. Hepatitis B reactivation in immunosuppressed patients, prophylaxis and management. *Indones J Gastroenterol Hepatol Dig Endosc* 2017;18:98-103.
7. Jang JW, Kim YW, Lee SW, Kwon JH, Nam SW, Bae AH, et al. Reactivation of Hepatitis B virus in HbsAg-negative Patients with hepatocellular carcinoma. *PLOS ONE* 2015;10:e0122041.
8. Wong WS, Leung WK, Chan HLY. Icteric flare of chronic hepatitis B in 95-year old patient. *World J Gastroenterol* 2003;9:2876-7.
9. Ware AJ, Cuthbert JA, Shorey J, Gurian LE, Eigenbrodt EH. A prospective trial of steroid therapy in severe viral hepatitis, the prognosis significance of bridging necrosis. *Gastroenterology* 1981;80:219-24.
10. Katz R, Ducci H, Alessandri H. Influence of cortisone and prednisolone in hyperbilirubinemia. *J Clin Invest* 1957;36:1370-4.
11. Aach RD. Corticosteroid and bilirubin metabolism. *Gastroenterology* 1969;56:363-6.
12. Terrault NA, Lok ASF, Mc MAhon BJ, Chang KM, Hwang JP, Jonas MM, et al. Update on prevention, diagnosis, and treatment of chronic hepatitis B: AASLD 2018 Hepatitis B Guidance. *Hepatology* 2018;67:1560-99.