

# Current Diagnosis and Treatment of Choledocholithiasis

*Kaka Renaldi<sup>1</sup>, Fauzan Hertrisno Firman<sup>2</sup>*

<sup>1</sup>Division of Gastroenterology, Pancreatobiliary, and Gastrointestinal Endoscopy,  
Department of Internal Medicine, Faculty of Medicine Universitas Indonesia  
Dr. Cipto Mangunkusumo Hospital

<sup>2</sup>Resident Internal Medicine Department, Faculty Medicine Universitas Indonesia,  
Cipto Mangunkusumo Tertiary Referral Hospital

## **Corresponding Author:**

*Kaka Renaldi, MD. Division of Gastroenterology, Pancreatobiliary, and Gastrointestinal Endoscopy, Department of Internal Medicine, Faculty of Medicine Universitas Indonesia Dr. Cipto Mangunkusumo Hospital. Jl Diponegoro 71, Jakarta 10430, Indonesia. email:kakarenaldi@gmail.com*

## **ABSTRACT**

*The presence of gallstones in the common biliary duct is known as choledocholithiasis. It can be classified as primary or secondary choledocholithiasis. Obstructive jaundice is the main clinical manifestation, which can cause acute cholangitis characterized by fever, jaundice, and right upper quadrant abdominal pain. The best diagnostic modality for choledocholithiasis is magnetic resonance cholangiopancreatography (MRCP). The treatment of choledocholithiasis involves extraction of gallstones using endoscopic retrograde cholangiopancreatography (ERCP), followed by stenting, and then cholecystectomy. For difficult cases, endoscopic papillary large balloon dilation can be attempted. The aim of this review is to discuss the current update of the diagnosis and treatment of choledocholithiasis.*

**Keywords:** choledocholithiasis, diagnosis, ERCP, treatment

## **ABSTRAK**

*Koledokolitiasis adalah penyakit yang disebabkan oleh adanya batu di ductus choledochus. Koledokolitiasis dapat diklasifikasikan sebagai primer atau sekunder. Gejala utamanya adalah pasien dapat mengalami ikterus obstuktif. Selain itu, dapat timbul komplikasi berupa kolangitis akut yang ditandai dengan adanya demam, ikterus, dan nyeri pada abdomen kuadran kanan atas. Modalitas diagnostik utama untuk koledokolitiasis adalah magnetic resonance cholangiopancreatography (MRCP). Tata laksana koledokolitiasis melibatkan ekstraksi batu empedu menggunakan endoscopic retrograde cholangiopancreatography (ERCP), diikuti dengan pemasangan stent dan kolesistektomi. Pada kasus sulit, dapat dilakukan endoscopic papillary large balloon dilation. Tujuan dari telaah literatur ini adalah untuk membahas perkembangan diagnosis dan tata laksana dari koledokolitiasis.*

**Kata kunci:** koledokolitiasis, diagnosis, ERCP, tata laksana

## INTRODUCTION

Choledocholithiasis, or gallstones within the common bile duct, is a common pancreatobiliary disease.<sup>1,2</sup> Gallstones in the common biliary duct can manifest clinically as obstructive jaundice, biliary colic, cholangitis, or biliary sepsis if the treatment is delayed. Choledocholithiasis mostly begins as cholelithiasis. The stones from the gallbladder can then move into the common bile duct, obstructing it and causing jaundice.<sup>1</sup> Additionally, choledocholithiasis can arise *de novo* in the duct itself.

Diagnostic imaging modalities for choledocholithiasis include abdominal ultrasound, CT scan, and magnetic resonance cholangiopancreatography (MRCP) to determine the level at which the obstruction is present, which is important for the treatment.<sup>1,2</sup> The treatment for choledocholithiasis is endoscopic retrograde cholangiopancreatography (ERCP) to extract the gallstones and insert a stent, followed by laparoscopic cholecystectomy.<sup>1,2,3</sup> The diagnostic and treatment modalities of choledocholithiasis are constantly evolving. Treatment using ERCP is still currently the gold standard, followed by laparoscopic cholecystectomy.<sup>1,2</sup>

## EPIDEMIOLOGY OF CHOLEDOCHOLITHIASIS

The prevalence of choledocholithiasis is reported to be 1–15% among the cholelithiasis cases in the United

States.<sup>1</sup> According to a National Health and Nutrition Examination Survey report, choledocholithiasis ranges from 5–20% among cholelithiasis cases, and around 20 million United States citizens experienced cholelithiasis. Choledocholithiasis prevalence increases with age, especially people above 50 years old.<sup>1,2</sup> Prevalence in different regions is reported to be 4.6–12% in Europe, 20.9% in South America, and 10–30% in China.<sup>3,4</sup>

Choledocholithiasis can arise primarily or secondarily.<sup>5</sup> Primary choledocholithiasis is defined as the formation of gallstones within the duct itself. In contrast, secondary choledocholithiasis is defined as gallstones within the common bile duct originating from the gallbladder. Another difference is the composition of the stones. Brown pigment is found in primary stones, while secondary stones primarily comprise cholesterol.<sup>5</sup>

## CLASSIFICATION OF CHOLEDOCHOLITHIASIS

Choledocholithiasis is grouped into two classifications: primary and secondary choledocholithiasis. Primary choledocholithiasis occurs because of biliary stasis that leads to the formation of gallstones in the common bile duct, according to Figure 1. Gallstones for med in the common bile duct mainly comprise bilirubin calcium salts, also known as brown pigment.

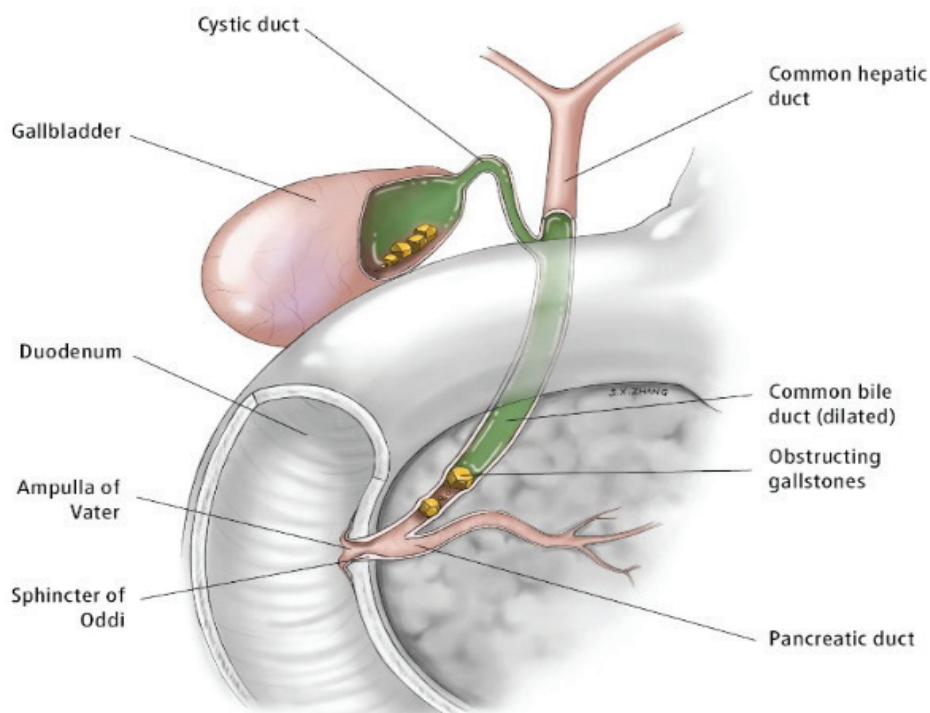


Figure 1. Choledocholithiasis<sup>1</sup>

Several conditions are associated with primary choledocholithiasis, which are as follows:

a. Cystic fibrosis

In cystic fibrosis, the gene encoding cystic fibrosis transmembrane conductance (CFTR) experiences a mutation.<sup>6</sup> This gene mutation impairs chloride secretion and increases sodium and water (H<sub>2</sub>O) reabsorption, increasing bile viscosity. Increased viscosity is a risk factor for biliary stasis that may develop into choledocholithiasis.<sup>6</sup>

b. Periapillary diverticula

These diverticula arise within a 2 to 3-cm radius of the major papilla, as shown in Figure 2.<sup>7</sup> The presence of a diverticulum at this anatomical region is a risk factor for primary choledocholithiasis.<sup>8,9</sup> The mechanism that causes choledocholithiasis is the collapse of the common bile duct by the external pressure, causing biliary stasis and choledocholithiasis.<sup>8,9</sup>

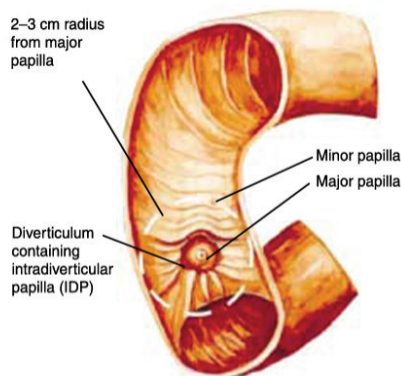


Figure 2. Periapillary Diverticula<sup>2</sup>

c. Recurrent infection

Infection of the bile duct, known as cholangitis, can become a risk factor for choledocholithiasis, especially primary choledocholithiasis.<sup>4,5</sup> An acute infection episode triggers the tissue healing process that consequently causes fibrosis. If recurrent, fibrosis will become significant, causing biliary stasis that facilitates the formation of primary choledocholithiasis.<sup>4,5</sup>

The second type of choledocholithiasis is secondary choledocholithiasis, which makes up most of choledocholithiasis cases.<sup>1</sup> In secondary choledocholithiasis, a preexisting cholelithiasis is spontaneously ejected into the common bile duct.<sup>1</sup> The gallstone within the duct triggers inflammation and causes infectious processes in the bile duct, known as cholangitis, as shown in Figure 3.

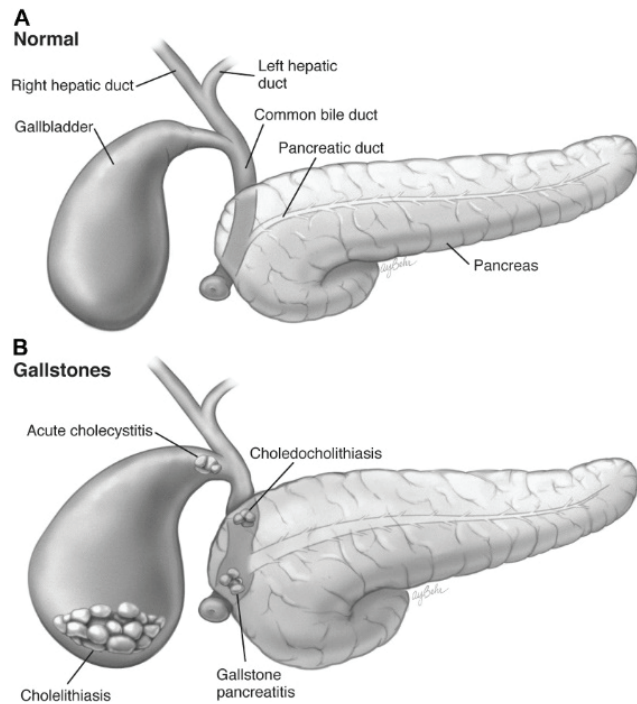


Figure 3. Secondary Choledocholithiasis Pathogenesis<sup>1</sup>

### IMAGING MODALITIES FOR CHOLEDOCHOLITHIASIS

The initial examination for choledocholithiasis based on the guidelines is abdominal ultrasound (Figure 4).<sup>11</sup> Diagnostic accuracy for abdominal ultrasound is good, with a sensitivity of 73% (95% CI 44%–95%) and specificity of 91% (95% CI 84%–95%).<sup>11</sup> The ultrasound will show multiple acoustic shadows and widening of the bile duct (>7 mm).

If abdominal ultrasound cannot establish the diagnosis, the next examination is endoscopic ultrasound (EUS) and MRCP. The accuracies for these two examinations are excellent. Research conducted by Meeralam Y (2017) demonstrates that the sensitivity and specificity for EUS are 97% and 87%, respectively; meanwhile, the sensitivity and specificity of MRCP are 90% and 92%, respectively.

EUS yields better sensitivity compared to MRCP because of its ability to detect smaller gallstones (<5 mm). EUS also can be done concurrently with ERCP, which is used to treat choledocholithiasis.

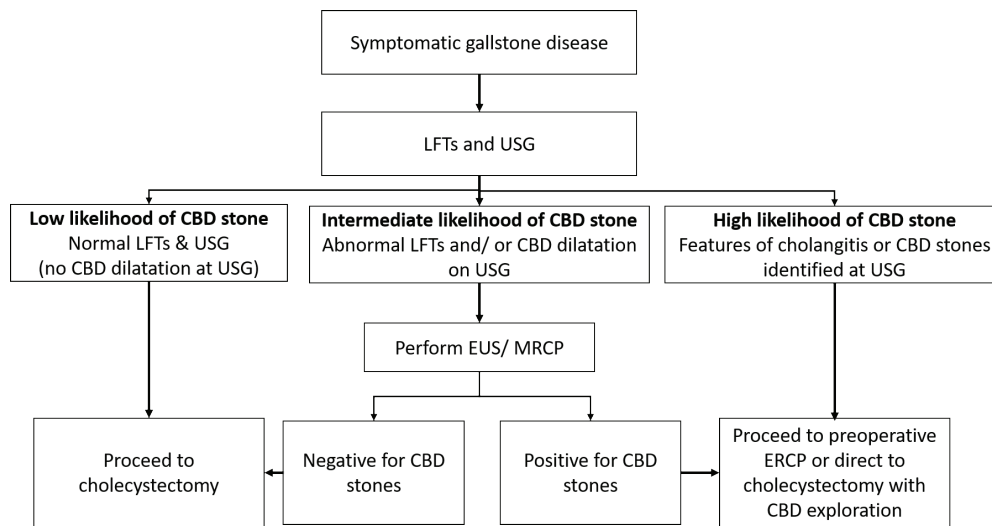


Figure 4. Diagnostic and Treatment Algorithm for Choledocholithiasis<sup>4</sup>

**PROPHYLACTIC ANTIBIOTICS FOR ERCP**

There is not enough evidence to support the administration of prophylactic antibiotics before ERCP. The ERCP procedure carries an infection risk during the administration of contrast and sphincterotomy, by causing the translocation of intraluminal bacteria into the bloodstream. However, a meta-analysis by Brand M (2010) demonstrates a lack of efficacy for prophylactic antibiotics in preventing infection after ERCP (RR 0,98 95% CI: 0,35-2,69).<sup>11,12</sup>

**CHOLEDOCHOLITHIASIS TREATMENT**

Adequate treatment of choledocholithiasis is crucial in preventing further complications. Possible complications include cholangitis and pancreatitis. After diagnosis, prompt ERCP is needed to extract the gallstones.<sup>11</sup> Research conducted by Harris A. et

al. (1999) shows a significant difference in cholangitis incidences between two groups, one that underwent extraction and another that did not. These incidences are 12.7% and 25.3% respectively (odds ratio OR 0.44; 95% CI: 0.35–0.55).<sup>12</sup> Gallstones larger than 4 mm demonstrate more significant risks of complication.<sup>12</sup>

Endoscopic sphincterotomy and balloon dilatation are also conducted during the ERCP procedure, as shown in Figure 5. Sphincterotomy is performed at the ampulla of Vater to facilitate the biliary drainage and stone extraction.<sup>14</sup>

Figure 6 showed endoscopic balloon dilation, which is also used to help facilitate biliary drainage and stone extraction.<sup>14</sup> The ballooning method is not recommended as the sole procedure because of its low success rates. However, this may be the sole procedure if coagulopathy is found and patients have high risk of bleeding from sphincterotomy.

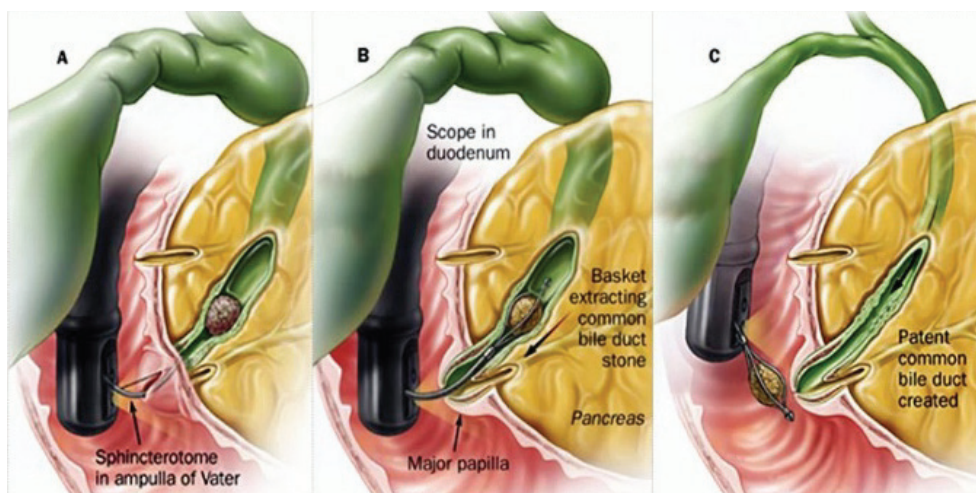


Figure 5. Sphincterotomy Method using ERCP<sup>3</sup>

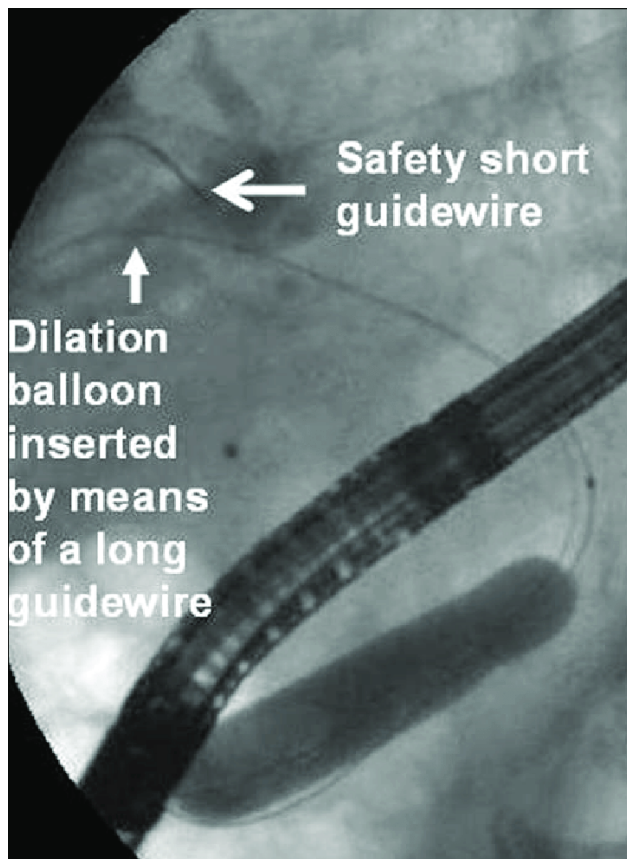


Figure 6. Ballooning Dilatation Method using ERCP<sup>4</sup>

### GALLSTONE EXTRACTION USING ERCP

Gallstone extraction from the common bile duct commonly involves two apparatuses: balloon and basket catheters, as shown in Figure 7. There remain inconsistencies between the efficacies of these two methods. Several research articles, one conducted by Ishiwatari H et al. (2016), state that for choledocholithiasis with a diameter of <1 cm, the balloon method provides better results than the basket method.<sup>15</sup>

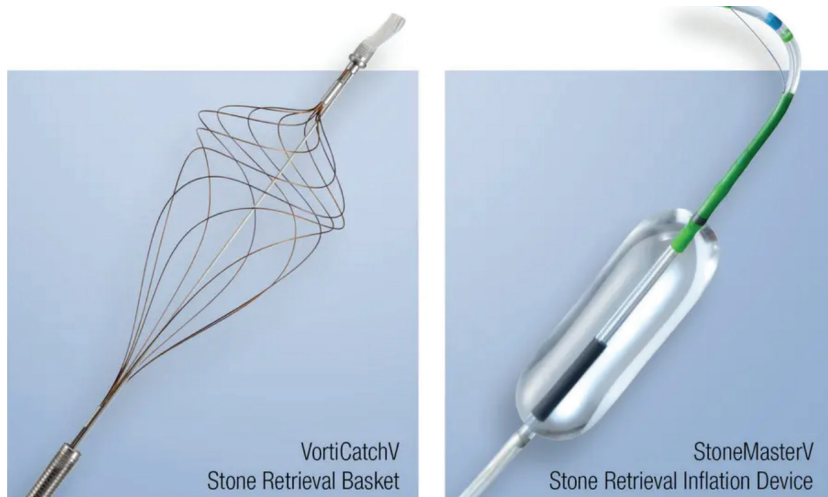


Figure 7. Basket and Ballooning Device for Choledocholithiasis Extraction<sup>5</sup>

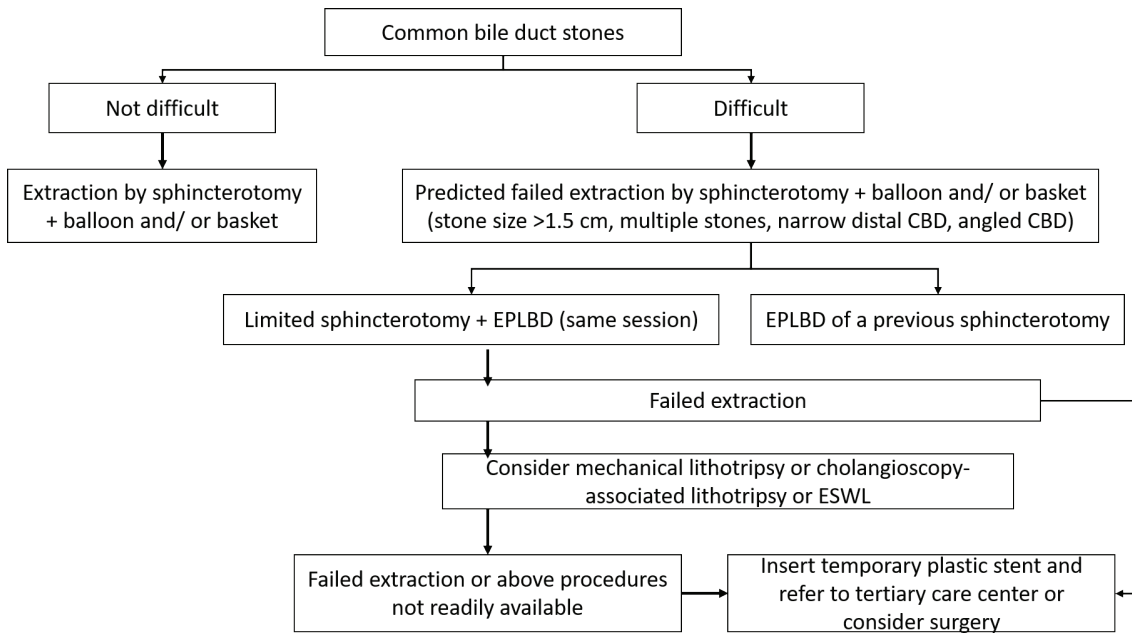
However, opposing results are reported by Ozawa N et al. (2017) that showed no significant difference between the two methods in gallstone extraction.<sup>16</sup> Nonetheless, for gallstones with a diameter of <6mm, it is stated that the balloon method has better success rates.<sup>16</sup> It can be concluded that the balloon method has better efficacy for gallstone extraction than the basket method.

If unsuccessful in completely extracting gallstones, a possible procedure is the installation of a plastic biliary stent. The friction formed between the gallstones and the stent reduces its size and allows exit through the stent. The interval between stent replacements is 3–6 months because long-term use can cause infection such as cholangitis.

The use of metal stents in treating choledocholithiasis has yet to be widely researched. A case series by Hartery K (2017) showed complete stones clearance after the installation of metallic stents in 40 patients.<sup>17</sup> However, clinical trials are still required to confirm the positive results.

### PHARMACOLOGICAL TREATMENT FOR CHOLEDOCHOLITHIASIS

Ursodeoxycholic acid is a drug known as a treatment for gallstones. This drug is known to reduce gallstone size and prevent the formation of gallstones. However, further research shows that this drug does not have the same efficacy as a treatment for choledocholithiasis and, therefore, is not regularly used.<sup>18</sup> This drug is not recommended to both treat and preventing recurrence of the gallstones.



Gambar 8. Therapeutic Modalities for Difficult Gallstones<sup>4</sup>

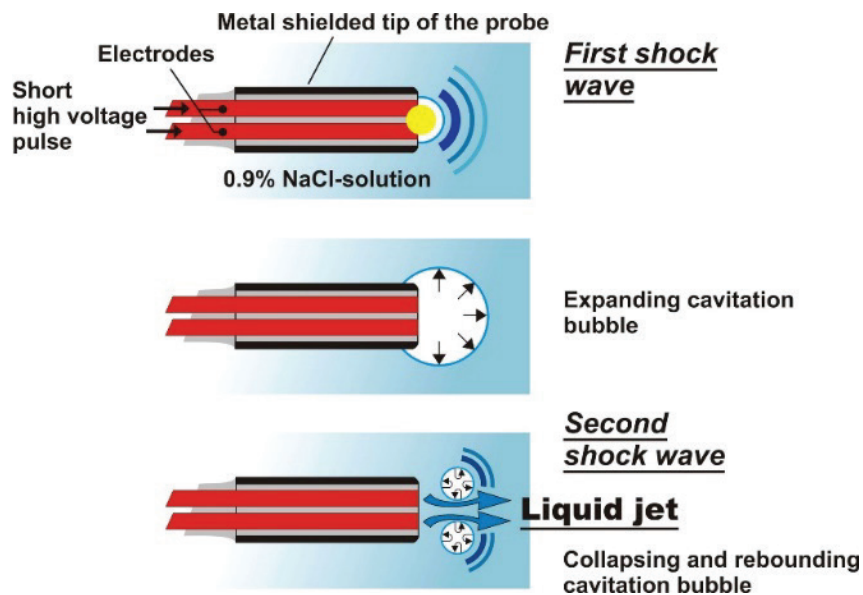


Figure 9. Electrohydraulic Lithotripsy<sup>4</sup>



Figure 10. Laser Lithotripsy<sup>4</sup>

## TREATMENT FOR DIFFICULT GALLSTONES

The criteria for difficult gallstones are as follows: diameter over 1.5 cm, barrel-shaped, sigmoid or located in the cystic and intrahepatic ducts, and stone impaction, as shown in Figure 8.<sup>11</sup> In these difficult gallstone cases, dilation of the bile duct uses endoscopic papillary large balloon dilation (EPLBD). The procedure uses a balloon with a diameter of 12 to 20 mm, then inflated for 1 minute to provide dilating effects, so that stone or biliary drainage can occur. This procedure is done after endoscopic sphincterotomy.<sup>11</sup>

After sphincterotomy and EPLBD, further therapeutic modalities for this case are<sup>11</sup>:

- a. mechanical lithotripsy, using the method of stone destruction with baskets, then altering the basket's size to be smaller to create relatively high pressure to make the stone's size smaller.
- b. electrohydraulic lithotripsy, which runs electrical pulses through an intermediary liquid medium, which produces shockwaves that can fracture gallstones into relatively smaller ones.
- c. Lithotripsy (as shown in Figure 9) using lasers to make the gallstone size smaller. The difference lies in the medium wherein it uses a laser wave, in contrast to electrical waves or mechanical waves, to make the stone's size smaller.
- d. extracorporeal shock wave lithotripsy (ESWL) uses electromagnetic waves from outside the body to the target organ, which in this case is the stone in the bile duct, to reduce its size. Nasobiliary drain is installed during the procedure for fluoroscopic imaging and normal saline irrigation. The irrigation causes stone fragments that may dislodge while the ESWL procedure is underway.

## POST-ERCP LAPAROSCOPIC CHOLECYSTECTOMY

After gallstone extraction by ERCP, laparoscopic cholecystectomy should be conducted.<sup>11</sup> This procedure aims to prevent the recurrent formation of stones. If cholecystectomy is not done, there are risks such as cholangitis, pancreatitis, and even repeated biliary colic when the stone reforms. Cholecystectomy is recommended promptly after ERCP to avoid incidents like cholangitis or recurrent gallstones. Cholecystectomy is recommended within two weeks after ERCP.<sup>11</sup>

If choledocholithiasis is found during cholecystectomy, intraoperative ERCP can be performed. A meta-analysis conducted by Tan C et al.

(2018) found that intraoperative ERCP has plenty of advantages, such as lower rate of morbidities, lower pancreatitis incidence, and shorter hospital stays.<sup>19</sup>

## ERCP TIME WINDOW FOR CHOLANGITIS

Cholangitis is an infection of the bile duct caused by choledocholithiasis. It has three grades of severity: mild, moderate, and severe.<sup>20</sup>

- a. Severe acute cholangitis, diagnosed by these indicators:
  - Hypotension that requires dopamine doses of  $>5$  mcg/kg/min or norepinephrine
  - Altered consciousness
  - PaO<sub>2</sub>/FiO<sub>2</sub> ratio  $<300$
  - Oliguria, creatinine  $>2$  mg/dL
  - INR  $>1.5$
  - Thrombocytopenia, below 100000
- b. Moderate acute cholangitis, diagnosed by at least two of the following indicators:
  - Leukocytosis,  $>12000$  or leukopenia,  $<4000$
  - Fever with a temperature above 39°C
  - Age  $>75$  years old
  - Total bilirubin  $>5$  mg/dL
  - Hypoalbuminemia,  $<0.7$  times the maximum normal reference range.
- c. Mild acute cholangitis, diagnosed if severe and moderate acute cholangitis criteria are not met

The time to do ERCP is based on the grade of the acute cholangitis. More severe cholangitis requires more immediate ERCP to perform biliary drainage, so that the infection source can be controlled adequately. Below is the recommended time to perform ERCP based on the grade of cholangitis:

- a. Severe acute cholangitis: as soon as possible and before 12 hours
- b. Moderate acute cholangitis: within 48–72 hours
- c. Mild acute cholangitis: electively

Delay to perform ERCP in cholangitis is known to cause mortality. This is associated with increased incidence of biliary sepsis, especially for severe acute cholangitis.

## CHOLEDOCHOLITHIASIS IN PREGNANCY

Choledocholithiasis may occur during pregnancy. The dilemma arises because ERCP uses radiation during its procedure. This radiation is known to be teratogenic. ERCP is recommended to be performed starting in the second trimester because organogenesis is still present during the first trimester, hence risking abnormalities with radioactive exposure.<sup>21</sup>

The radiation may also be given at a relatively smaller dose at 10 mGy to minimize its effects on the fetus. Guidance using ultrasound and cholangioscopy are also used to minimize the effects of radiation. Research conducted by Tang S et al. (2009) observed a reduced incidence of congenital malformations, stillbirth, and fetal death in 59 pregnant women who underwent ERCP.<sup>21</sup> Recently, ERCP without fluoroscopy has also been attempted in order to reduce the radiation exposure, with similar technical success as conventional ERCP.<sup>22</sup>

## CONCLUSION

Choledocholithiasis is a common biliary disease. Early diagnosis is necessary to prevent the complication such as cholangitis. Various treatments including ERCP need to be performed to prevent infectious complications, which will increase the patient's mortality rate.

## REFERENCES

- McNicol CF, Pastorino A, Farooq U, et al. Choledocholithiasis. [updated 2021 Aug 31]. In: StatPearls [Internet]. Treasure Island (FL): StatPearls Publishing [cited 22 Jan 2023]. Available from: <https://www.ncbi.nlm.nih.gov/books/NBK441961/>
- Baiu I, Hawn MT. Choledocholithiasis. *JAMA*. 2018 Oct 9;320(14):1506.
- Collins C, Maguire D, Ireland A, Fitzgerald E, O'Sullivan GC. A prospective study of common bile duct calculi in patients undergoing laparoscopic cholecystectomy: natural history of choledocholithiasis revisited. *Ann Surg*. 2004 Jan;239(1):28-33.
- Tazuma S. Gallstone disease: Epidemiology, pathogenesis, and classification of biliary stones (common bile duct and intrahepatic). *Best Pract Res Clin Gastroenterol*. 2006;20(6):1075-83.
- Molvar C, Glaenger B. Choledocholithiasis: Evaluation, Treatment, and Outcomes. *Semin Intervent Radiol*. 2016;33(4):268-276.
- Assis DN, Debray D. Gallbladder and bile duct disease in Cystic Fibrosis. *J Cyst Fibros*. 2017
- Lobo DN, Balfour TW, Iftikhar SY, Rowlands BJ. Periampullary diverticula and pancreaticobiliary disease. *Br J Surg*. 1999 May;86(5):588-97.
- Major P, et al. A Periampullary Duodenal Diverticula in Patient with Choledocholithiasis - Single Endoscopic Center Experience. *Pol Przegl Chir*. 2016 Dec 1;88(6):328-333.
- Kim MH, et al. Association of periampullary diverticula with primary choledocholithiasis but not with secondary choledocholithiasis. *Endoscopy*. 1998 Sep;30(7):601-4.
- Wilkins T, Agabin E, Varghese J, Talukder A. Gallbladder Dysfunction: Cholecystitis, Choledocholithiasis, Cholangitis, and Biliary Dyskinesia. *Prim Care*. 2017 Dec;44(4):575-597.
- Manes G, Paspatis G, Aabakken L, Anderloni A, Arvanitakis M, Ah-Soune P, et al. Endoscopic management of common bile duct stones: European Society of Gastrointestinal Endoscopy (ESGE) guideline. *Endoscopy*. 2019 May;51(5):472-491.
- Harris A, Chan AC, Torres-Viera C, Hammett R, Carr-Locke D. Meta-analysis of antibiotic prophylaxis in endoscopic retrograde cholangiopancreatography (ERCP). *Endoscopy*. 1999 Nov;31(9):718-24.
- Meeralam Y, Al-Shammari K, Yaghoobi M. Diagnostic accuracy of EUS compared with MRCP in detecting choledocholithiasis: a meta-analysis of diagnostic test accuracy in head-to-head studies. *Gastrointest Endosc*. 2017 Dec;86(6):986-993.
- Testoni PA, et al. Papillary cannulation and sphincterotomy techniques at ERCP: European Society of Gastrointestinal Endoscopy (ESGE) Clinical Guideline. *Endoscopy*. 2016 Jul;48(7):657-83.
- Ishiwatari H, et al; Hokkaido Interventional EUS/ERCP Study (HONEST) Group. Balloon catheter versus basket catheter for endoscopic bile duct stone extraction: a multicenter randomized trial. *Endoscopy*. 2016 Apr;48(4):350-7.
- Ozawa N, et al. Prospective randomized study of endoscopic biliary stone extraction using either a basket or a balloon catheter: the BasketBall study. *J Gastroenterol*. 2017 May;52(5):623-630.
- Hartery K, et al. Covered self-expanding metal stents for the management of common bile duct stones. *Gastrointest Endosc*. 2017 Jan;85(1):181-186.
- Yamamoto R, Tazuma S, Kanno K, Igarashi Y, Inui K, Ohara H, Tsuyuguchi T, Ryozaawa S. Ursodeoxycholic acid after bile duct stone removal and risk factors for recurrence: a randomized trial. *J Hepatobiliary Pancreat Sci*. 2016 Feb;23(2):132-6.
- Tan C, Ocampo O, Ong R, Tan KS. Comparison of one stage laparoscopic cholecystectomy combined with intra-operative endoscopic sphincterotomy versus two-stage pre-operative endoscopic sphincterotomy followed by laparoscopic cholecystectomy for the management of pre-operatively diagnosed patients with common bile duct stones: a meta-analysis. *Surg Endosc*. 2018 Feb;32(2):770-778.
- Kiriyama S, et al. Tokyo Guidelines 2018: diagnostic criteria and severity grading of acute cholangitis (with videos). *J Hepatobiliary Pancreat Sci*. 2018 Jan;25(1):17-30.
- Tang SJ, Mayo MJ, Rodriguez-Frias E, Armstrong L, Tang L, Sreenarasimhaiah J, Lara LF, Rokey DC. Safety and utility of ERCP during pregnancy. *Gastrointest Endosc*. 2009 Mar;69(3 Pt 1):453-61.
- Cappell MS, Stavropoulos SN, Friedel D. Systematic review of safety and efficacy of therapeutic endoscopic-retrograde-cholangiopancreatography during pregnancy including studies of radiation-free therapeutic endoscopic-retrograde-cholangiopancreatography. *World J Gastrointest Endosc*. 2018;10(10):308-321.